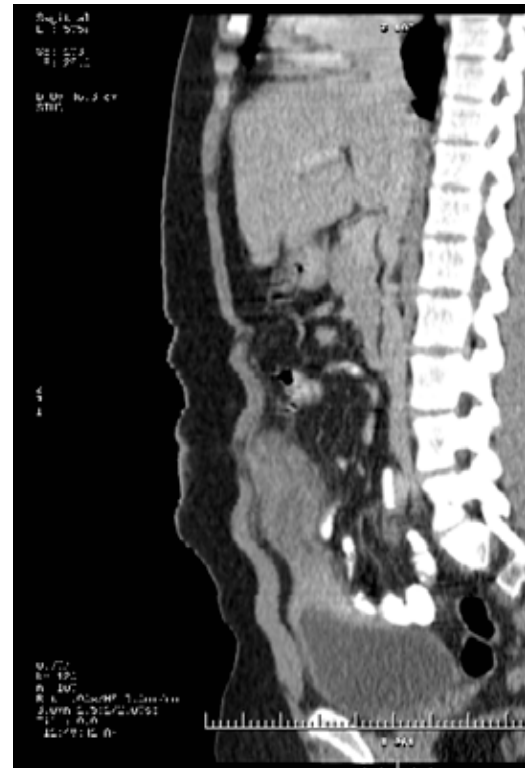
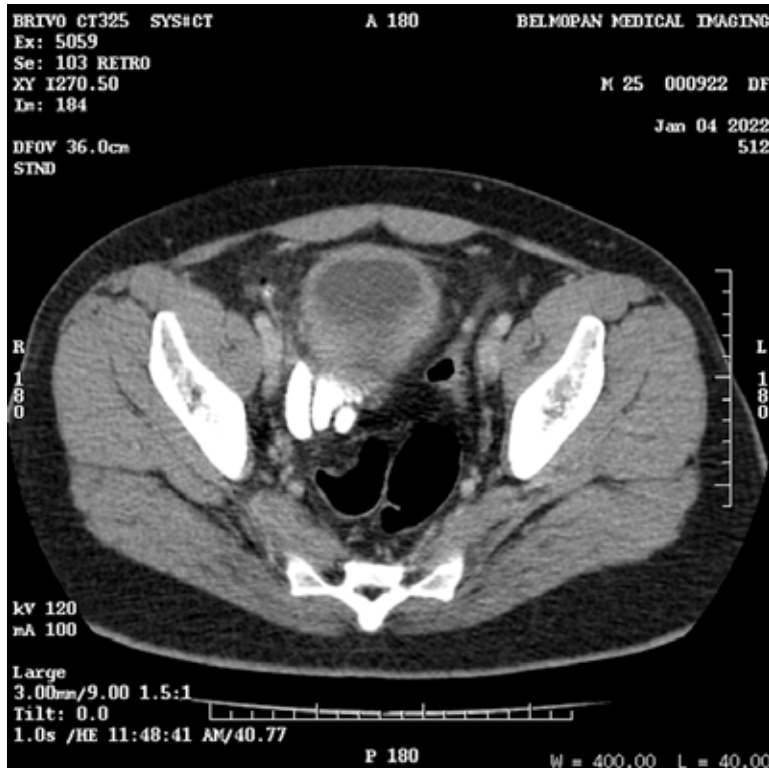
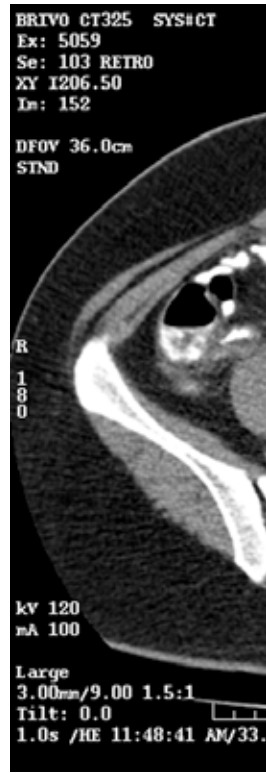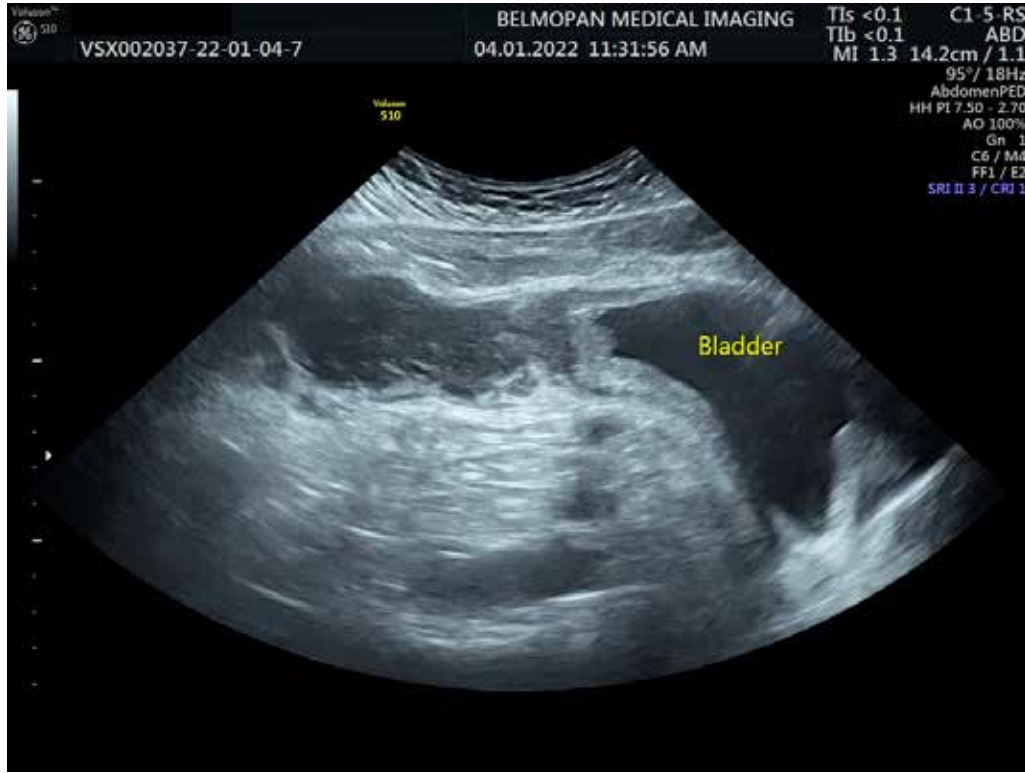RADIOGRAPHIC QUIZ

**25-year old male patient
with lower abdominal pain**



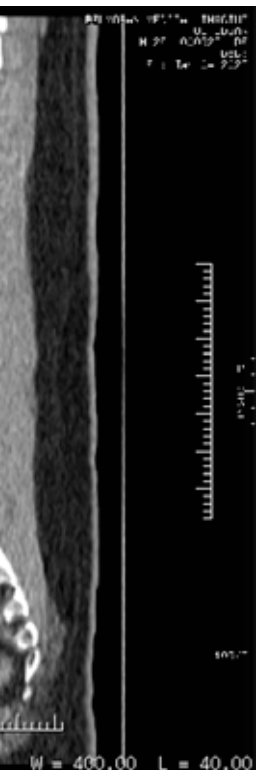
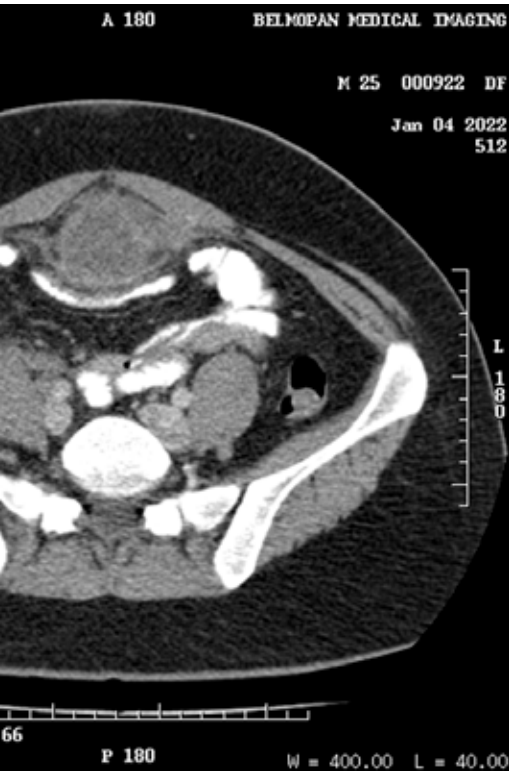


• Please respond ...

Julio Manuel Díaz Riverol¹

Citation:

Díaz Riverol JM. Radiographic quiz
BJM 2021; 10(2):16-17



Please answer to the following with TRUE or FALSE regarding the salient abnormality and associated findings.

There is an enhancing rim

-----True

-----False

There is adenopathy

-----True

-----False

There is bladder invasion

-----True

-----False

There is free fluid

-----True

-----False

There is perilesional fat stranding

-----True

-----False

Where does this mass most likely originate from?

-----Bladder

-----Peritoneum

-----Small bowel

-----None of the above

What is the diagnosis (single best answer, if any)?

-----Ureteritis cystica

-----Hutch diverticulum

-----Urachal anomaly

-----Ureteral diverticulum

-----None of the above

What is the most likely etiology of this lesion?

-----Infected urachal tract remnants

-----Umbilical urachal sinus

-----Vesicourachal diverticulum

-----Urachal cyst

Answers on page 35

.....
1 MD, Radiologist.
Belmopan Medical Imaging Center.
Email: diazriverol@hotmail.com