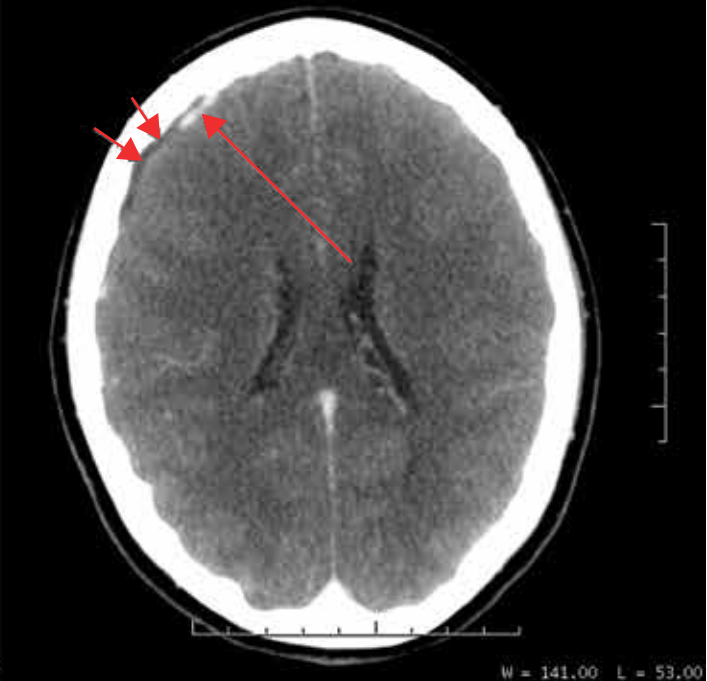
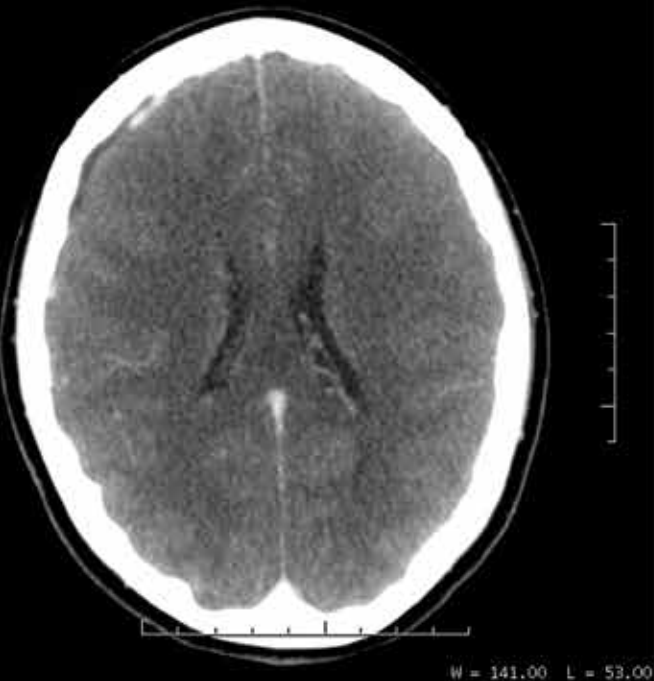
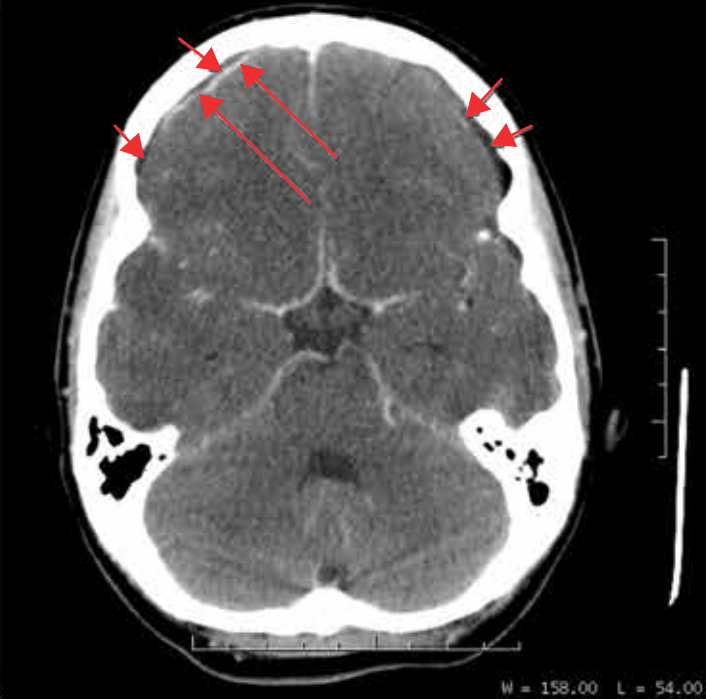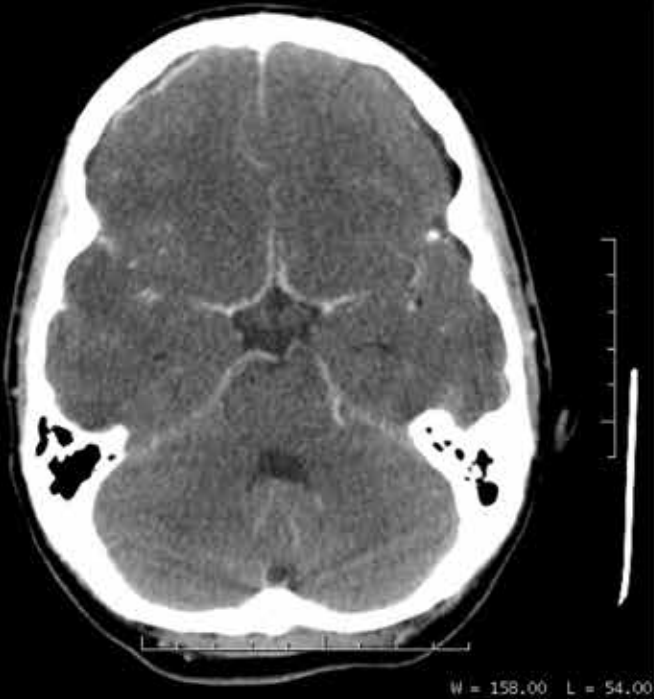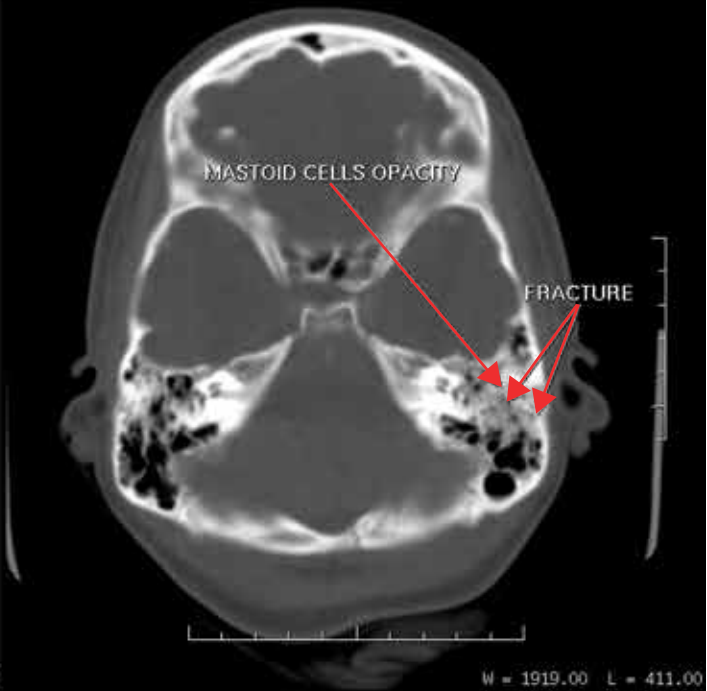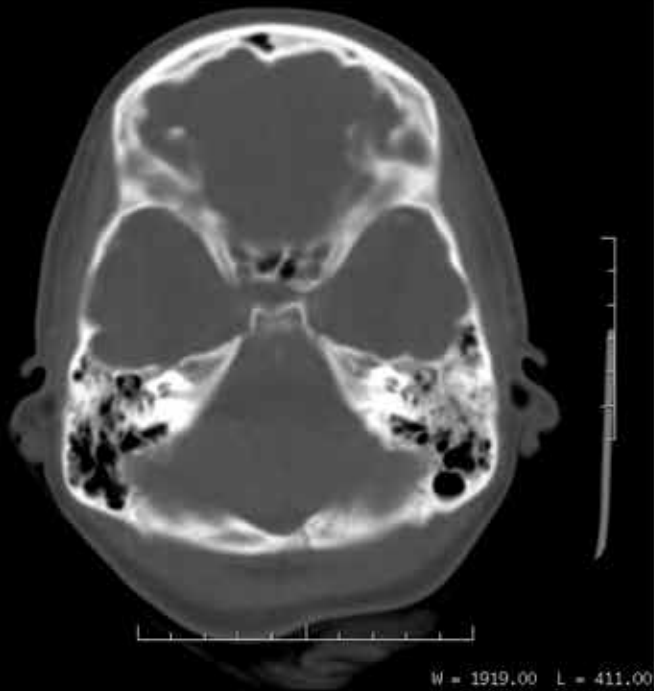## ■ IMAGE DESCRIPTION

There is left temporal linear fracture and opacity of the mastoid cells indicative of posttraumatic mastoiditis.

There is contrast enhancement of the leptomeninges.

There is bilateral subdural effusion.

There is effacement of the cerebral sulci indicative of brain edema.

## ■ DIAGNOSIS

Posttraumatic acute meningitis

## ■ BRIEF OVERVIEW OF THE DISEASE

Meningitis is a disease caused by the inflammation of the protective membranes covering the brain and spinal cord known as the meninges.

The brain has some unique peculiarities like: absence of lymphatics, lack of capillaries in the subarachnoid space, and presence of cerebrospinal fluid (CSF), which is an excellent culture medium for dissemination of infectious processes, in the subarachnoid space and into the ventricular system.

Meningitis is the most frequent infection of the CNS. Patients with the cardinal features of meningitis (headache, fever, altered sensorium, and meningismus) are presumed to have meningitis until proved otherwise. Approximately half of the imaging studies of acute meningitis show no specific imaging abnormalities. Nevertheless, imaging is indicated: to exclude space-occupying lesions; to exclude an alternate cause such as a subarachnoid hemorrhage; to assess for hydrocephalus; and to evaluate the potential sources of infection that might necessitate intervention beyond medical therapy, such as sinusitis, mastoiditis, or an empyema.

Contrast enhancement is generally useful, and in the light of clinical history and examination findings, the radiologist can provide a probable differential diagnosis. Whereas analysis of CSF remains the gold standard to identify the infectious agent, neuroimaging plays a pivotal role not only in diagnosis but also in monitoring therapeutic response.

Leptomeningeal enhancement is usually associated with meningitis, which may be bacterial, viral, or fungal. Bacterial and viral meningitis exhibit typically thin and linear enhancement, whereas fungal meningitis usually produces thicker, lumpy, or nodular enhancement. Neoplasms may spread into the subarachnoid space and produce enhancement of the brain surface and subarachnoid space, a pathologic process that is often called carcinomatous meningitis. Both primary tumors (medulloblastoma, ependymoma, glioblastoma, and oligodendroglioma) and secondary tumors (eg, lymphoma and breast cancer) may spread through the subarachnoid space. Neoplastic disease in the subarachnoid space may produce thicker, lumpy, or nodular enhancement, similar to that of fungal disease. Viral encephalitis (as well as sarcoidosis) may also produce enhancement along the cranial nerves, in addition to the brain surface. Normal cranial nerves never enhance within the subarachnoid space, and such enhancement is always abnormal.

Imaging studies are not used for the initial diagnosis of menin-

gitis. Only 50% of patients with meningitis show subarachnoid space enhancement. Therefore, the role of neuroimaging is to confirm suspected meningitis, to rule out meningitis mimics and increased intracranial pressure before lumbar puncture, and to evaluate for complications. In cases of uncomplicated meningitis, cranial CT seems to be sufficient for clinical management to exclude acute brain edema, hydrocephalus, and disease of the base of the skull. The most common signs of complicated meningitis are an enlarging head (in children) and increased intracranial pressure (persistent headache, nausea, vomiting, papilloedema, and focal deficits). These patients need imaging, preferably using MR imaging.

Currently, MRI is the most sensitive imaging modality, because the presence and extent of inflammatory changes in the meninges, as well as complications, can be detected. MRI is superior to CT scanning in the evaluation of patients with suspected meningitis, as well as in demonstrating leptomeningeal enhancement and distention of the subarachnoid space with widening of the interhemispheric fissure, which is reported to be an early finding in severe meningitis.

In uncomplicated cases of purulent meningitis, early CT scans and MRIs usually demonstrate normal findings or small ventricles and effacement of sulci. The value of CT scanning in the early diagnosis of subdural empyema is limited because of the presence of bone artifact.

Enhancement of the meninges is seen on contrast-enhanced CT scans and MRIs in cases of bacterial meningitis. However, meningeal enhancement is nonspecific and may also be caused by the following 5 different etiologic subgroups:

- Infectious.
- Carcinomatous meningitis.
- Reactive (eg, surgery, shunt, trauma).
- Chemical (eg, ruptured dermoid and cysticercoid cysts, intrathecal chemotherapy).
- Inflammatory (eg, sarcoidosis, collagen vascular disease).

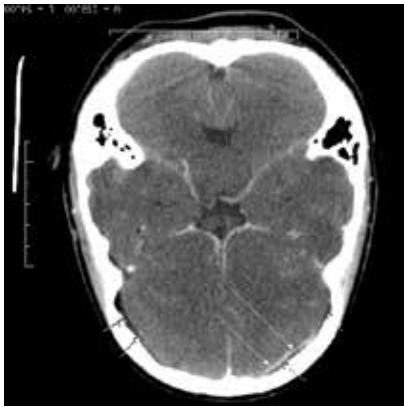Fractures of the temporal bone are common in patients with major head trauma, with a reported incidence of 18%–22% of skull fractures involving the temporal bone.

The longitudinal fracture type is more common (80%–90% of temporal bone fractures) and results from temporoparietal impact.

## ■ REFERENCES:

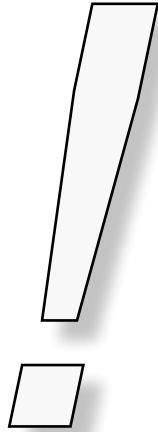
1. Patrick M. Capone, MD, PhD. Joseph M. Scheller MD. Neuroimaging of Infectious Disease. *Infectious Disease Clinics*. February 2014. Volume 32, Issue 1, Pages 127 -145.
2. Aisha T. Liferidge MD, MPH. Janae E.P. Dark, MD, MPH. Fever and Neurologic Conditions. *Emergency Medicine Clinics*. November 2013. Volume 31, Issue 4, Pages 987 -1017.
3. Lutfi Incesu, MD; Chief Editor: James G Smirniotopoulos, MD. Imaging in bacterial meningitis. *Medscape*. Nov 28, 2015

# Answer to Radiographic Quiz



Given the appearance of abnormalities and clinical history what is the primary diagnosis to consider?

- Acute brain infarcts.
- Acute hemorrhage.
- Brain tumor.
- Acute meningitis.



Please respond to the following with TRUE or FALSE regarding the salient findings.

- Is there any evidence of skull fracture?
- There is bilateral subdural effusion.
- There is evidence of parenchymal abscess.
- There is leptomeningeal enhancement.
- There are watershed and lacunar infarcts.
- There is effacement of the cerebral sulci indicative of brain edema.
- Is there any other abnormality no mentioned before?
- Opacity of the left mastoid cells indicative of mastoiditis secondary to trauma.

