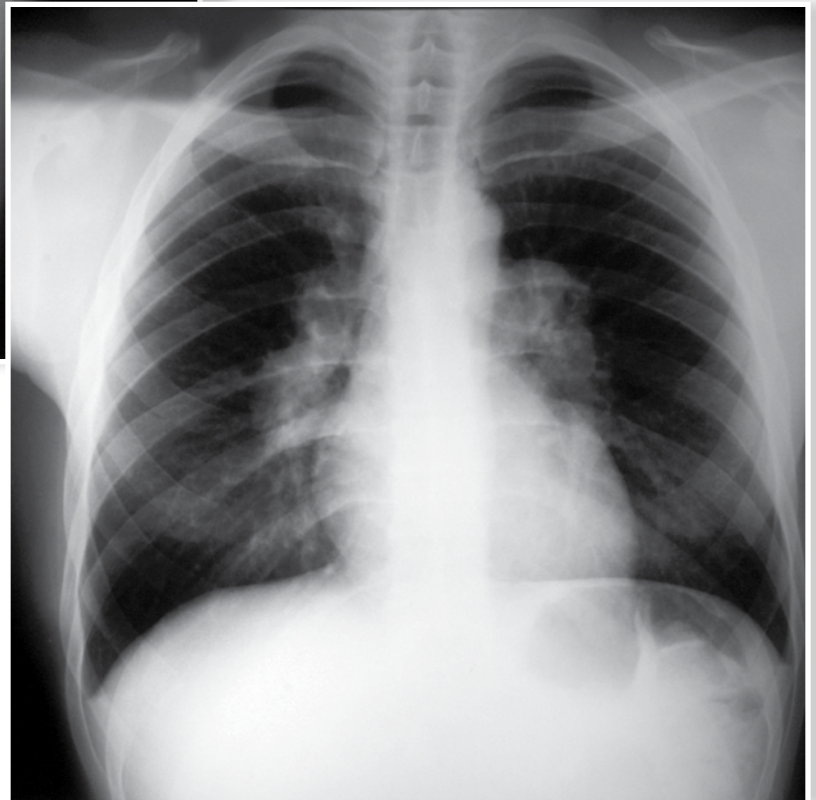
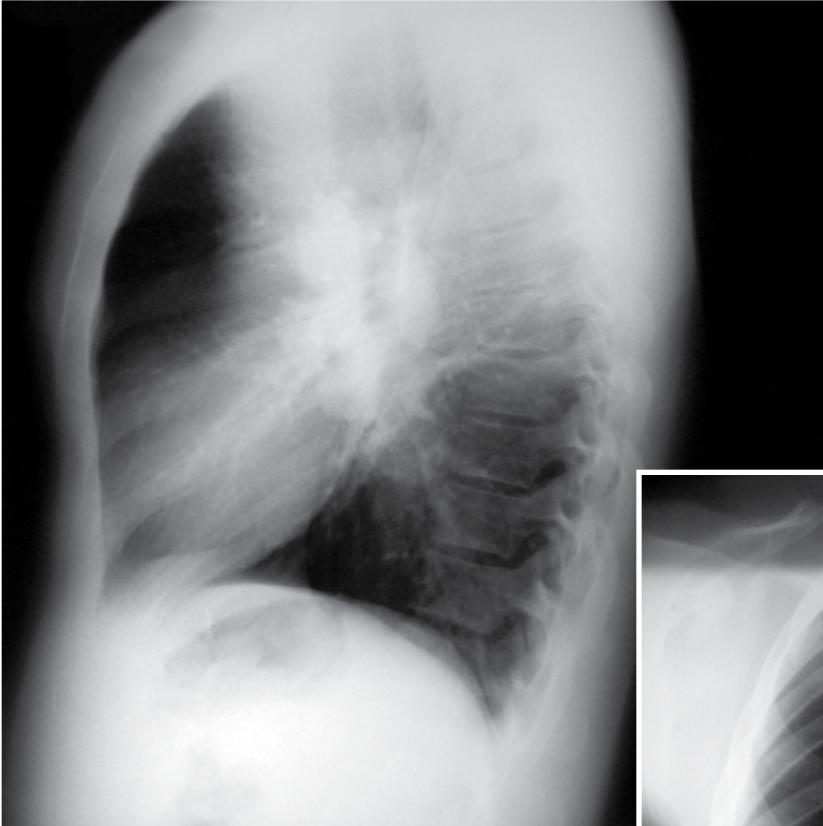


Radiographic quiz

Julio Manuel Diaz Riverol¹, Virginia Smith²

27 year old man with fatigue and general malaise. PA and lateral chest radiographs are shown below.

- A. Describe the radiographic findings.
- B. What is your probable diagnosis?
- C. What is your differential diagnosis?



.....
1. Corresponding author: Julio Manuel Diaz Riverol MD,
Radiologist, Belize Healthcare Partners, Belmopan Medical Imaging
Center. Email: diazriverol@hotmail.com

.....
2. MD, Radiologist, Belize Healthcare Partners, Belmopan Medical
Imaging Center