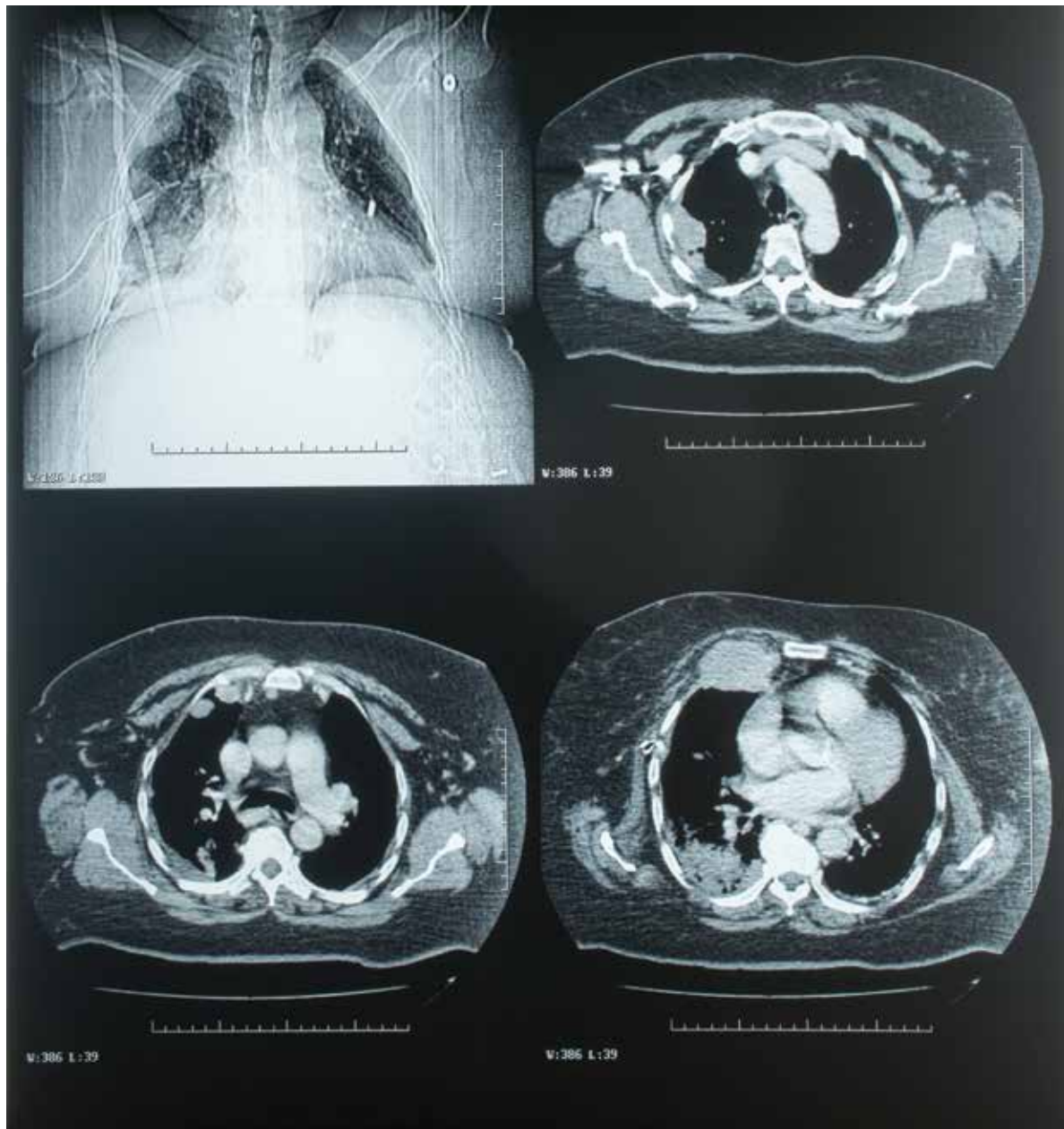


RADIOGRAPHIC QUIZ

Julio Manuel Díaz Riverol

MD, Radiologist, Belize Healthcare Partners, Belmopan Medical Imaging Center.
Email: diazriverol@hotmail.com

57 year old female patient complaining of shortness of breath.
Scout view of the chest CT scan and 3 axial views are shown below



Which choice best correlates with the findings?

- Acute infectious or inflammatory process
- Chronic infectious or inflammatory process
- Old trauma
- Malignancy
- Congenital anomaly

Please respond to the following
with TRUE or FALSE regarding the salient finding.

- Nodular pleural thickening
- Right pleural effusion
- Chest wall invasion
- Mediastinal adenopathy
- Lytic lesions of the spine

Which choice most likely corresponds
with the radiographic abnormalities?

- Bronchogenic carcinoma
- Pulmonary metastases
- Mesothelioma
- Chronic obstructive pulmonary disease (COPD)

