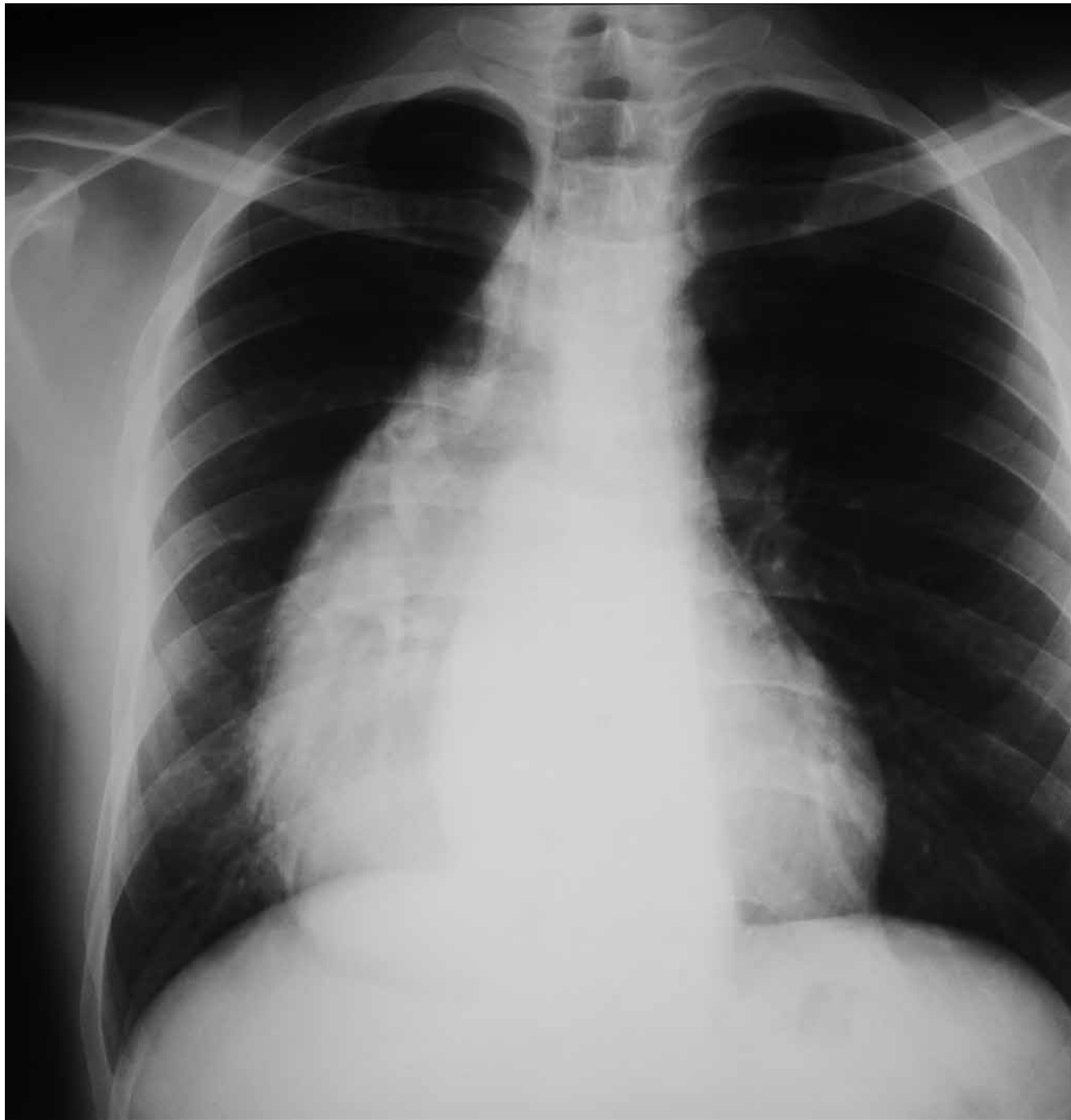

RADIOGRAPHIC QUIZ

27 years old male patient with chest pain and discomfort

Posterior-Anterior and lateral views of the chest are shown below



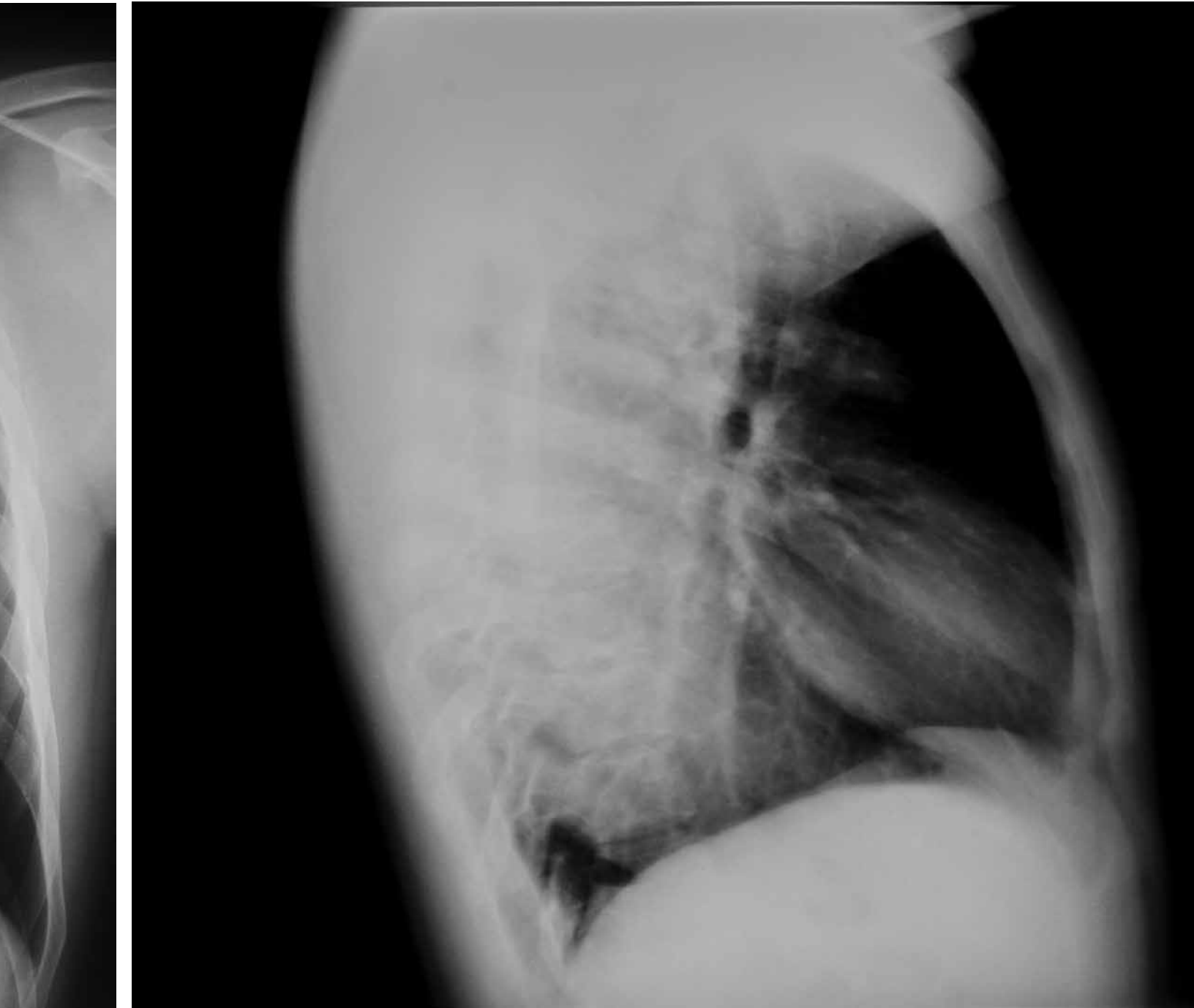
• Please respond true (T) or false (F)

Review both views before proceeding with the quiz

- Cardiomegaly
- Dilatation of the thoracic aorta
- Decreased volume of the right lung
- Widening of the mediastinum
- Right paramediastinal radiopacity
- Rib fractures
- Signs of pulmonary emphysema

Considering the abnormality detected in the previous radiographs which study would you request next?

- Plain chest CT
- Contrast chest CT
- Barium swallow
- Chest MRI



What is the most common clinical presentation in patients with this pathology?

- Chest pain and discomfort*
- Dysphagia which is for both solids and fluids*
- Eventual regurgitation*
- All of the above*

¹ MD, Radiologist, Belize Healthcare Partners, Belmopan Medical Imaging Center. Email: diazriverol@hotmail.com

² MD, Head of Critical Care, Karl Heusner Memorial Hospital, Princess Margaret Drive, Belize City, Belize