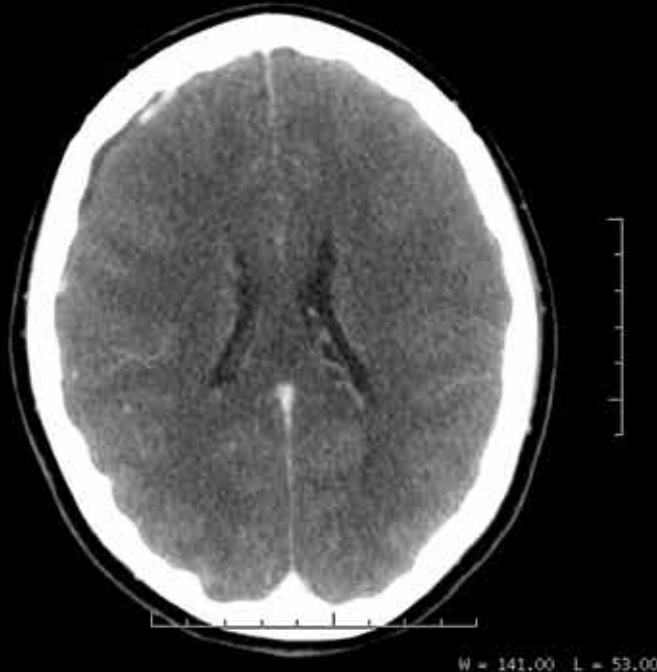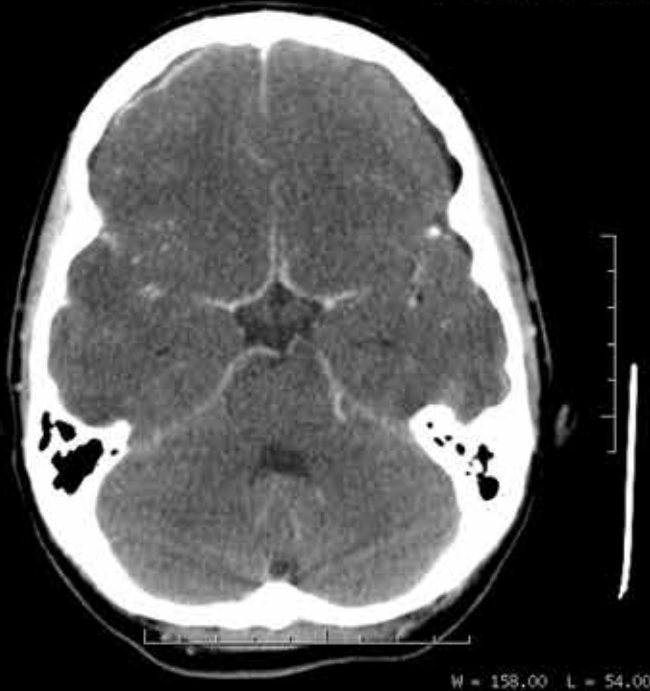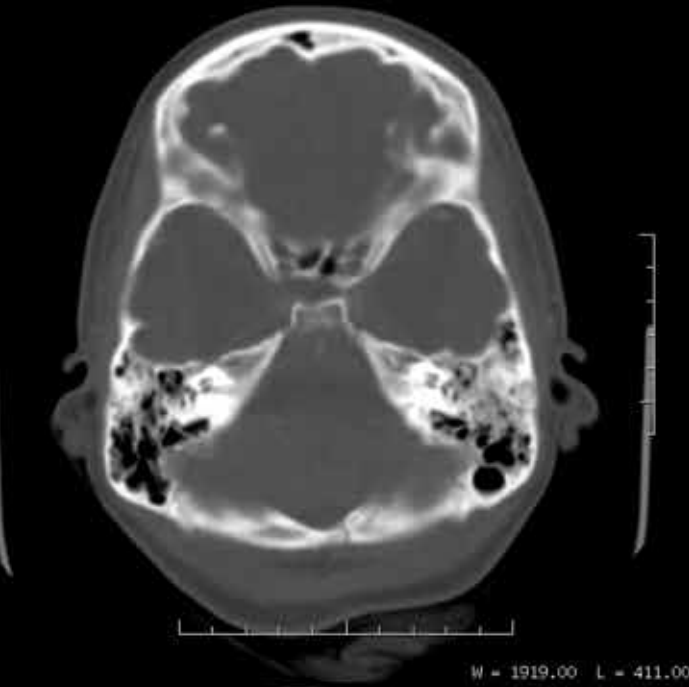


RADIOGRAPHIC QUIZ



20 years old female patient

with clinical history

of road traffic accident one week

ago. She was admitted and treated

in the hospital. Today she came back to the

emergency department complaining

of intense headache and fever.

WBC count: 24,000 mcl

Contrast enhanced brain CT images are shown at left.

• Please respond true (T) or false (F)

Please respond to the following with TRUE or FALSE regarding the salient findings

- _____ *Is there any evidence of skull fracture?*
- _____ *There is bilateral subdural effusion.*
- _____ *There is evidence of parenchymal abscess.*
- _____ *There is leptomeningeal enhancement.*
- _____ *There are watershed and lacunar infarcts.*
- _____ *There is effacement of the cerebral sulci indicative of brain edema.*
- _____ *Is there any other abnormality no mentioned before?*



Given the appearance of abnormalities and clinical history what is the primary diagnosis to consider?

- _____ *Acute brain infarcts.*
- _____ *Acute hemorrhage.*
- _____ *Brain tumor.*
- _____ *Acute meningitis.*



1 Dr. Julio Manuel Díaz, MD, Radiologist, Belize Healthcare Partners, Belmopan Medical Imaging Center
Email: diazriverol@hotmail.com

2 Dr. Jorge Hidalgo, MD, Adult intensive care specialist, Belize Healthcare Partners, Karl Huesner Memorial Hospital
Email: jluishidalgo58@hotmail.com