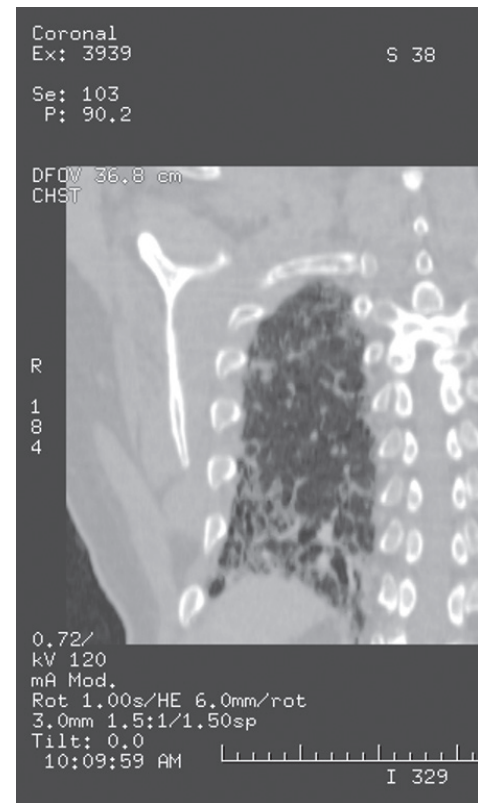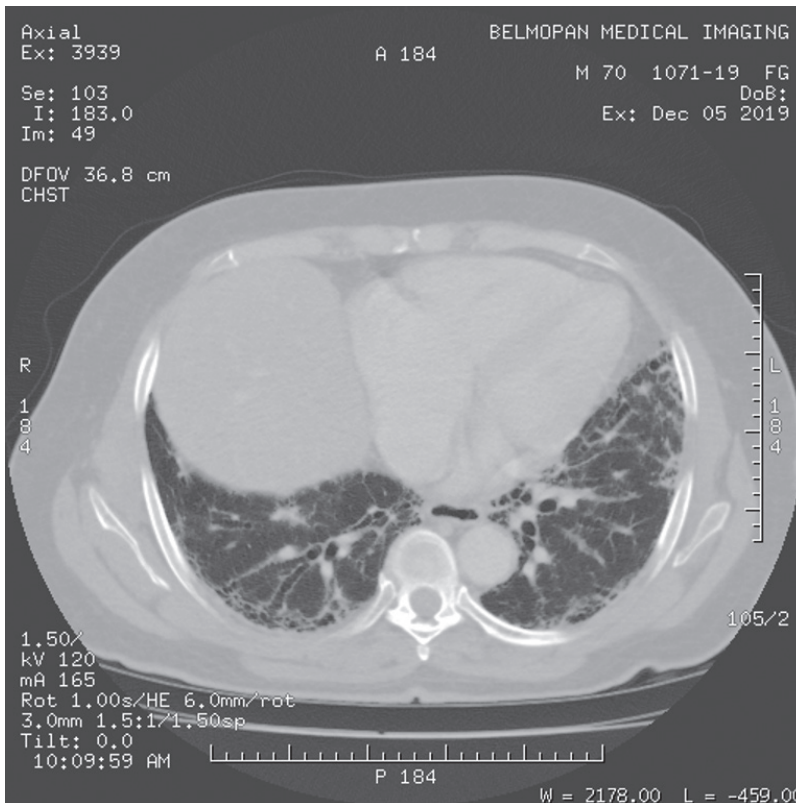
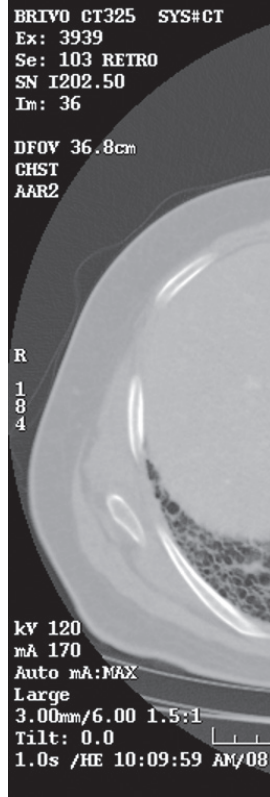

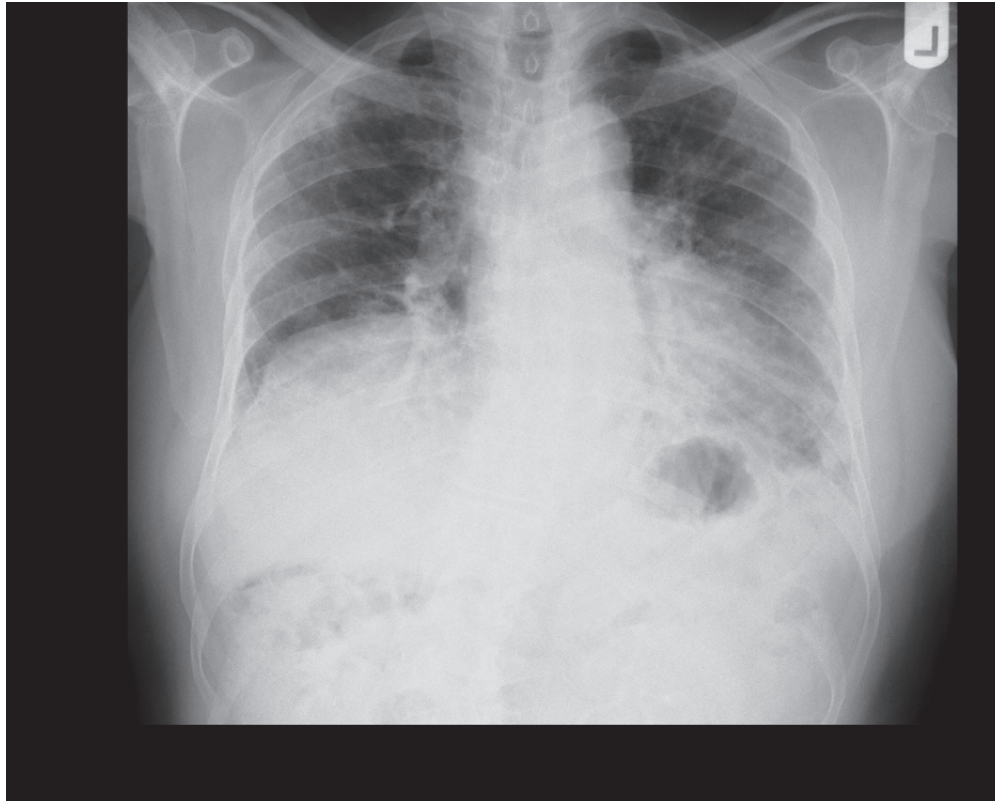
RADIOGRAPHIC QUIZ

Smoker, 70-year-old man

presents with productive cough and bilateral rales.

Frontal chest x ray and axial and reformatted chest CT images are provided.

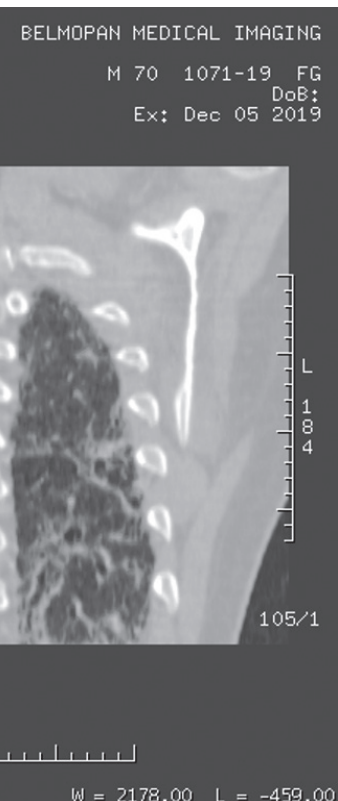
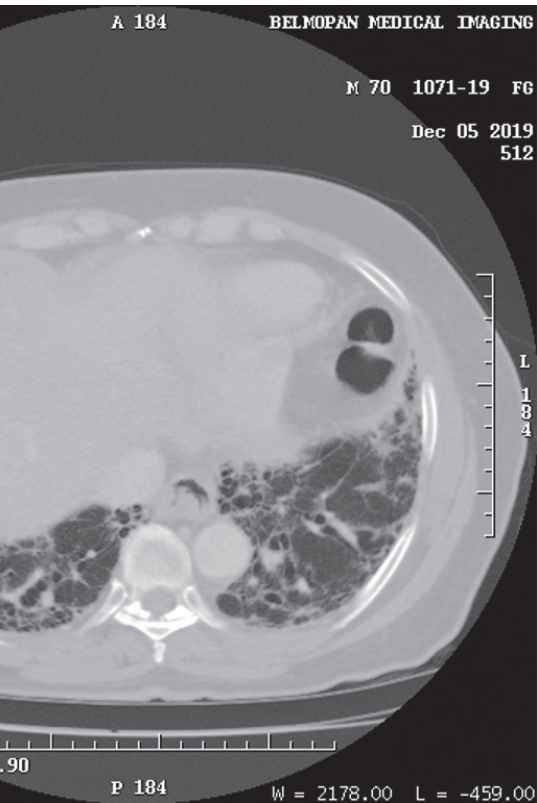


• Please respond ...

Julio Manuel Díaz Riverol¹



esented.



1. Which of the following findings are present on the chest x ray?

- A. Linear scarring
- B. Hilar retraction
- C. Peripheral patchy opacities
- D. Elevation of the right hemidiaphragm
- E. Right lower pulmonary opacity.

2. Which of the following findings are visible on the chest CT images?

- A. Peripheral honeycombing
- B. Reticular opacities
- C. Pneumothorax
- D. Pleural effusion
- E. Traction bronchiectasis

Answers on page 39

¹ MD, Radiologist.
Belmopan Medical Imaging Center.
Email: diazriverol@hotmail.com