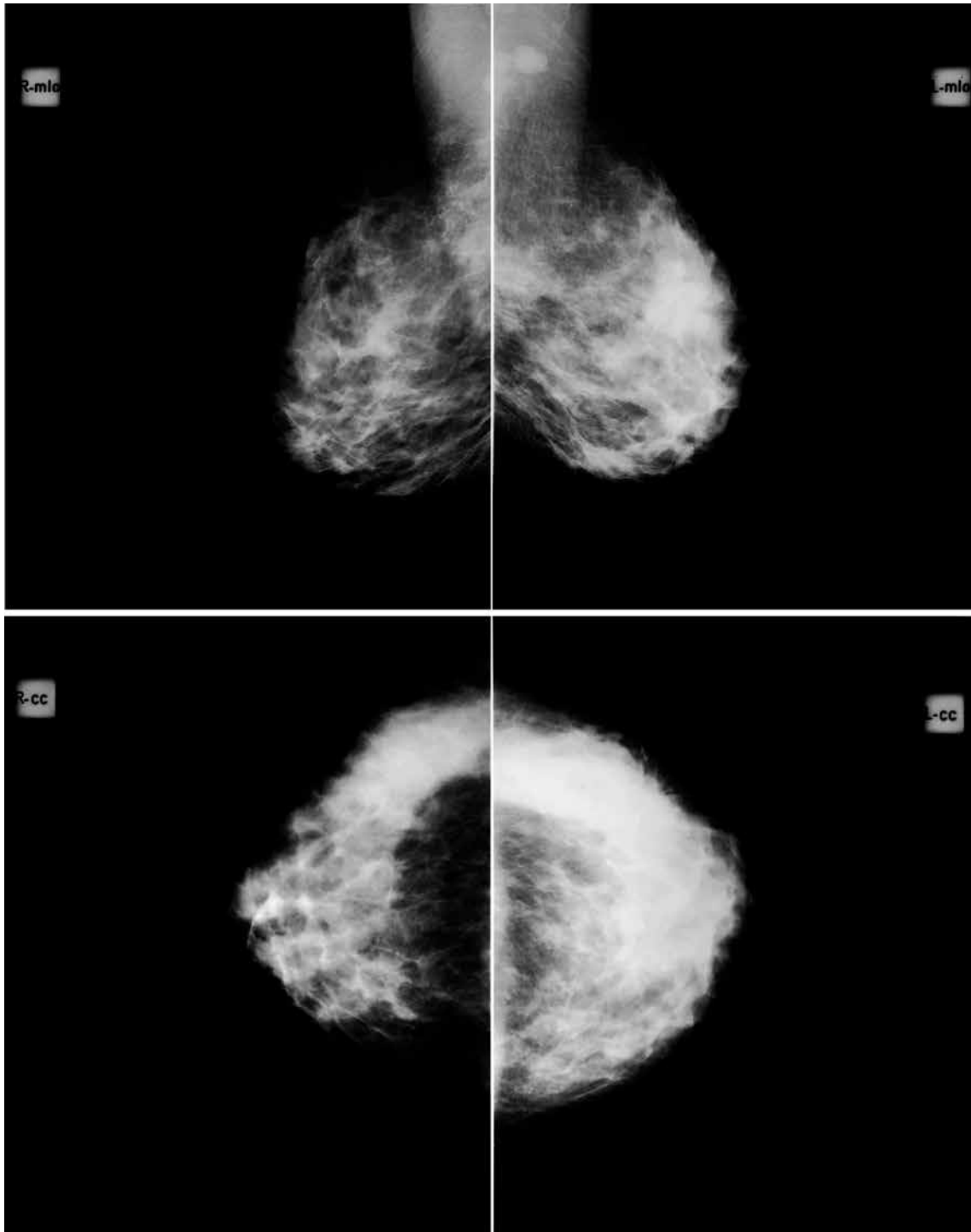


RADIOGRAPHIC QUIZ



Fifty-year old woman undergoing screening mammography . Mammograms 1 – 4
Please respond to the following with TRUE or FALSE regarding the salient findings.

- There are pleomorphic calcifications.
 - Skin thickening
 - There is global asymmetry.
 - Bilateral malignant finding
 - There is a spiculated irregular mass on the left breast.
 - There is a spiculated irregular mass on the right breast.
 - There is axillary adenopathy
 - The lesion has a very high likelihood of being malignant.
 - Targeted ultrasound would be a reasonable next step.
- Which is the most appropriate BIRADS classification?
 BIRADS 2 BIRADS 3 BIRADS 4 BIRADS 5