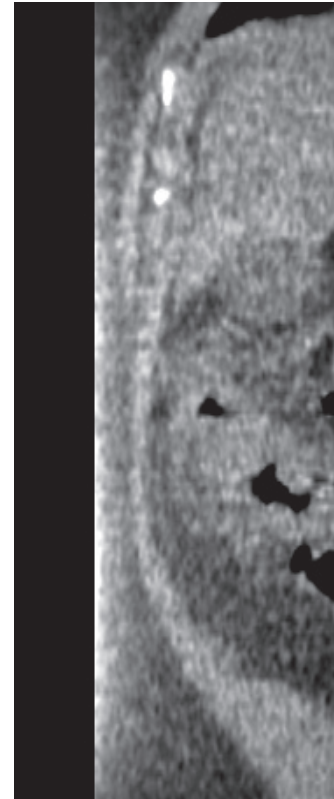
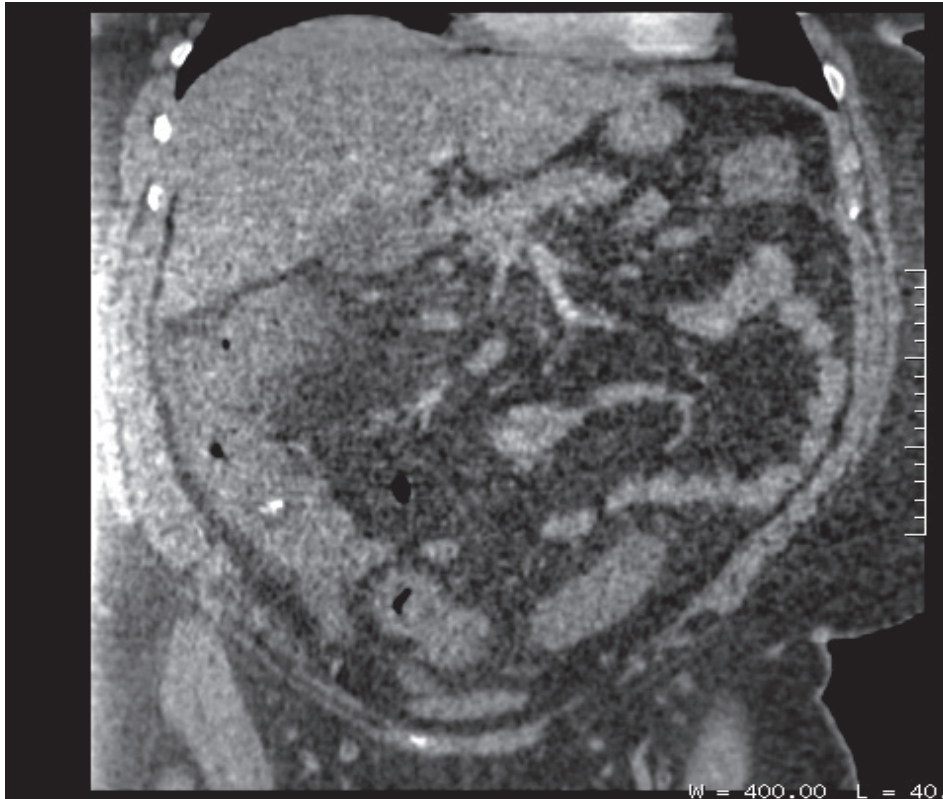
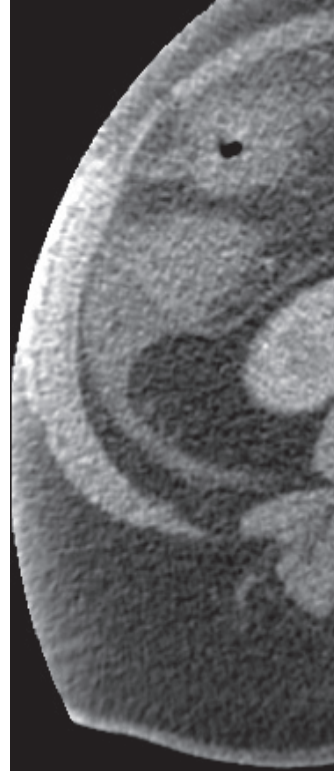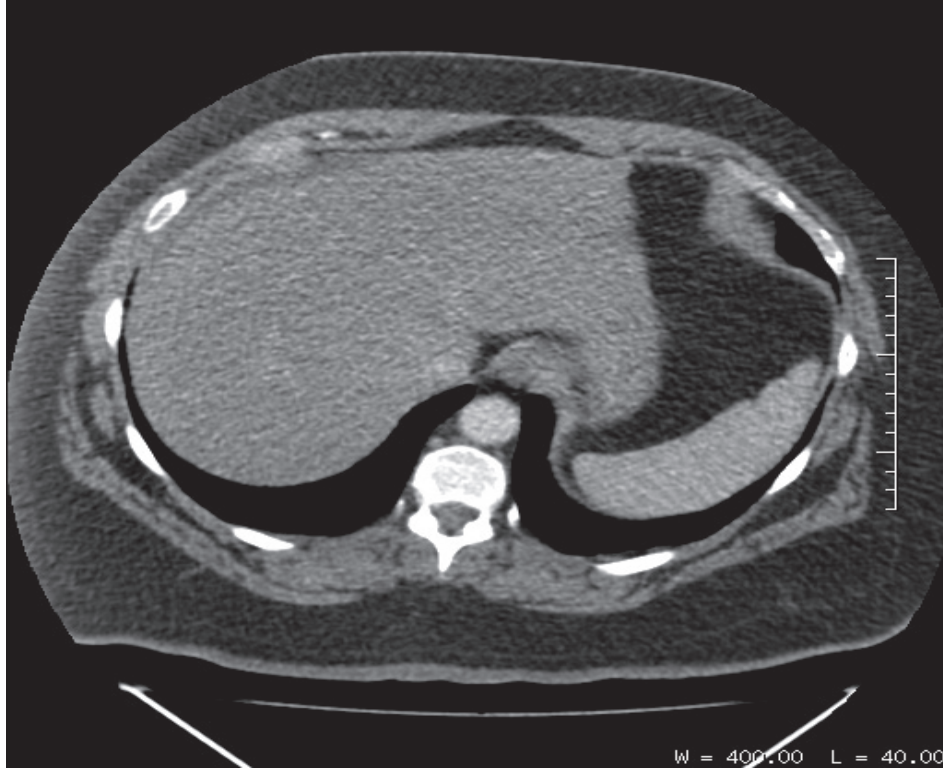


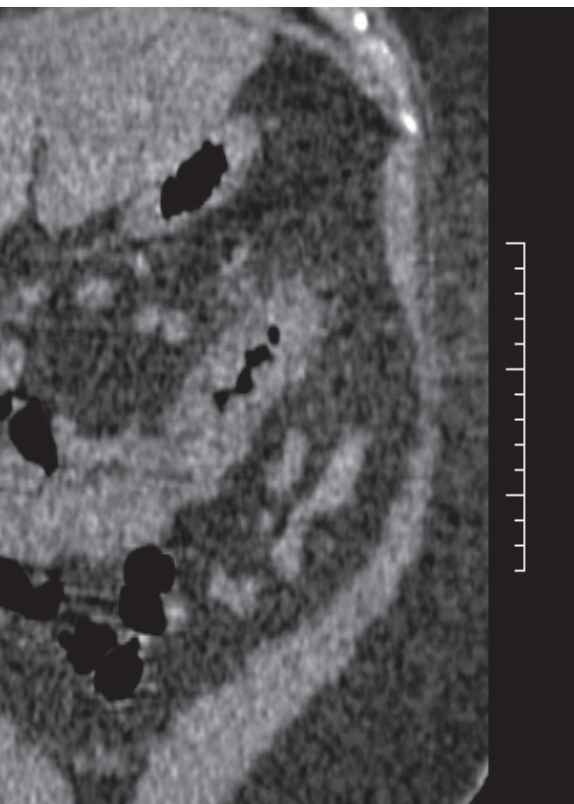
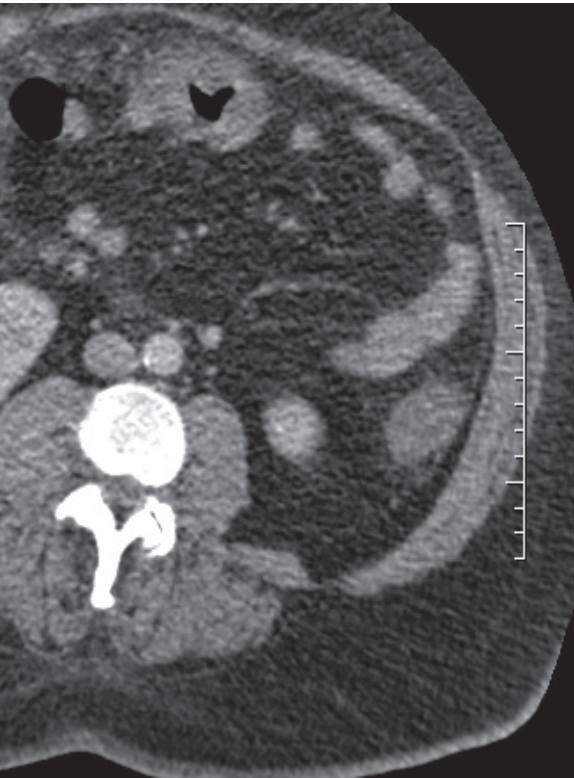
# RADIOGRAPHIC QUIZ

A 52-year-old female patient presents to the emergency department with abdominal pain and bloody diarrhea. A contrast-enhanced CT scan of the abdomen and pelvis was performed.



# ? • Please respond ...

Julio Manuel Díaz Riverol<sup>1</sup>



Where is the abnormality located?

- Liver*
- Retroperitoneum*
- Large intestine*
- Small intestine*

There is a small fluid collection adjacent to the tip of the liver and in the right iliac fossa

- True*
- False*

There is evidence of pneumoperitoneum

- True*
- False*

There is evidence of diverticular disease

- True*
- False*

What is the most likely etiology of the abnormality?

- Congenital*
- Neoplastic*
- Toxic/metabolic*
- Vascular*
- Infectious*

What is the most likely diagnosis?

- Infectious colitis*
- Diverticulitis*
- Peritoneal carcinomatosis*
- Hepatic cirrhosis*
- PID*

Answers on page 31

<sup>1</sup> MD, Radiologist, Belize Healthcare Partners, Belmopan Medical Imaging Center. Email: diazriverol@hotmail.com