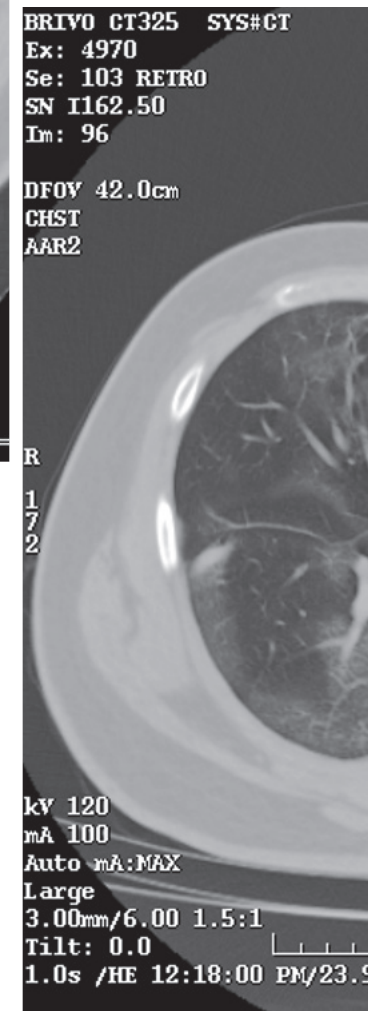
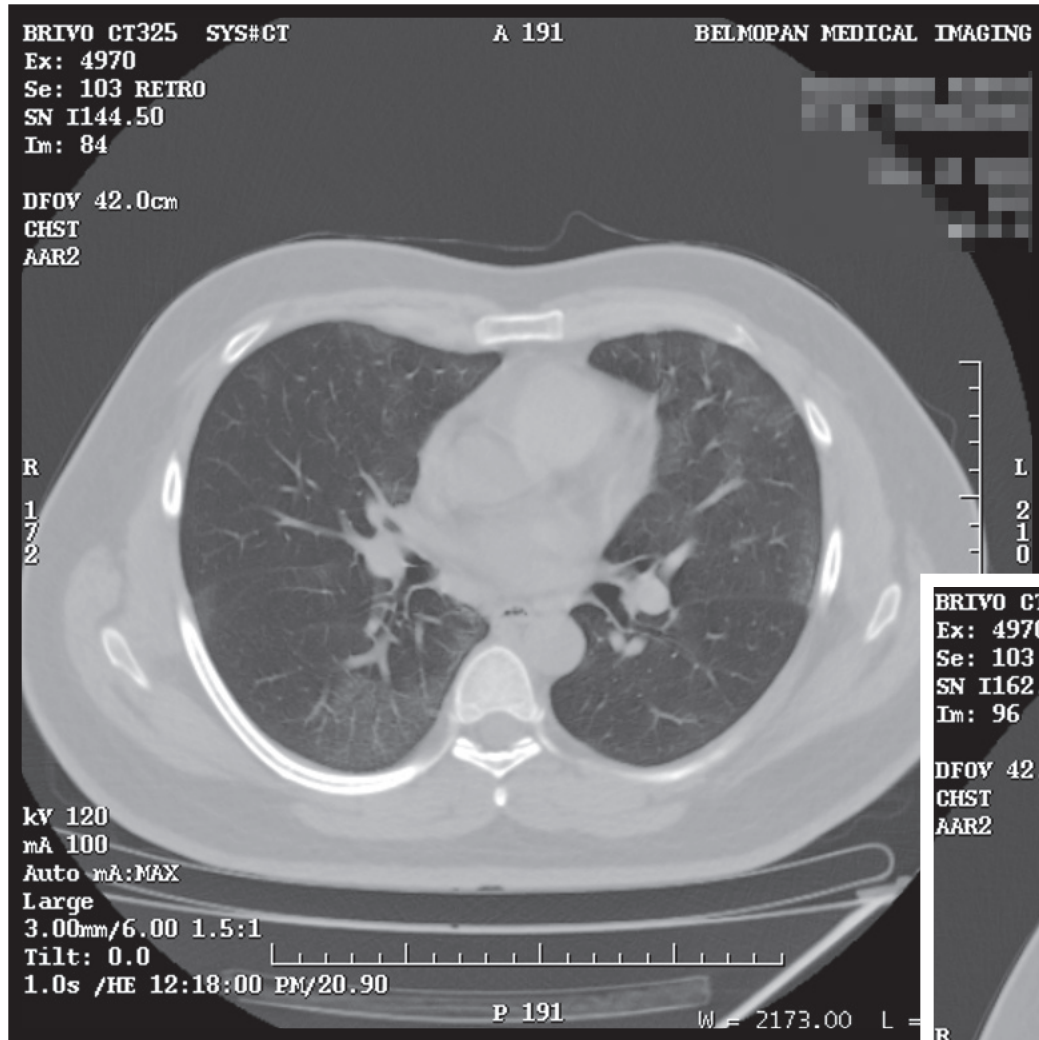


RADIOGRAPHIC QUIZ

46-year-old male patient

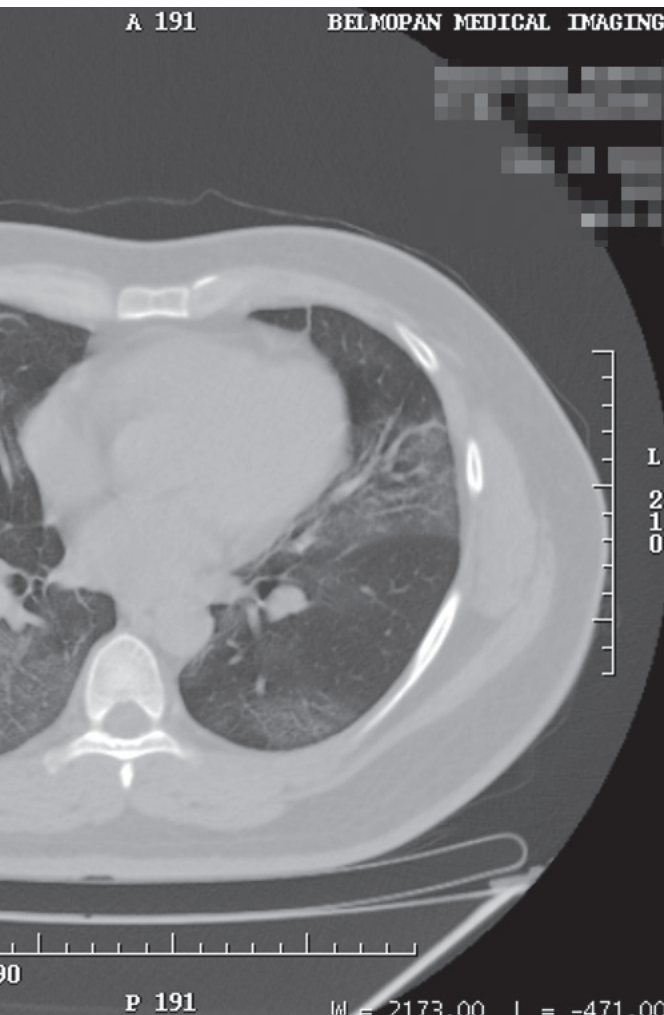

complaining of fever, cough and fatigue.

Two axial images of the plain chest CT scan are shown



• Please respond ...

Julio Manuel Díaz Riverol¹



Citation:

Díaz Riverol JM. Radiographic quiz BJM 2021; 10(1):12–13

1. What is the salient abnormality?

- Bilateral segmentary atelectasis*
- Pleural effusion*
- Cardiomegaly*
- Bilateral ground glass opacities*
- Pleural thickening*

2. Based on the clinical information and CT images, what is the most likely cause of the pulmonary lesions?

- COVID-19 pneumonia*
- Alveolar-cell carcinoma*
- Pulmonary fibrosis*
- Pulmonary sarcoidosis*

Answers on page 39

¹ MD, Radiologist.
Belmopan Medical Imaging Center.
Email: diazriverol@hotmail.com