

RADIOGRAPHIC QUIZ

From page 20

■ BRIEF OVERVIEW OF THE DISEASE

Hemophilia is an X-linked recessive disease affecting males. Hemarthrosis may be spontaneous or result from minor trauma and typically first occurs before the age of two and continues occurring into adolescence. It is usual for the same joint to be repeatedly involved. In adulthood, hemarthroses are uncommon. However, proliferative chronically-inflamed synovium results in the development of hemophilic arthropathy.

Hemophilic arthropathy (HA) refers to permanent joint disease occurring in hemophilia sufferers as a long-term consequence of repeated hemarthrosis. Around 50% of patients with hemophilia will develop a severe arthropathy.

Intra-articular bleeding is the most common clinical manifestation of hemophilia, and can adversely affect joints and lead to arthropathy. Affected joints are associated with changes to the synovium, bone, cartilage and blood vessels.

Recurrent hemorrhage into the joint leads to hemosiderin deposition, which has a direct degenerative toxic effect on the cartilage. Hemosiderin also stimulates synovial hypertrophy and inflammation, and repeated synovitis also leads to the progressive destruction of cartilage and subchondral bone. In essence, a combination of degenerative joint damage with inflammatory processes, occurring in parallel from the early stages of the disease, results in a fibrotic destroyed joint with resultant severe functional impairment.

There is synovial hyperplasia, chronic inflammation, fibrosis, and hemosiderosis. The synovium mass erodes cartilage and subchondral bone leading to subarticular cyst formation.

Hemophilic arthropathy is often monoarticular or oligoarticular. Large joints are most commonly involved in the following order of frequency:

1. knee
2. elbow
3. ankle
4. hip
5. shoulder

■ RADIOGRAPHIC FEATURES

PLAIN RADIOGRAPH

- joint effusion is seen in the setting of hemarthrosis
- periarticular osteoporosis: from hyperemia
- epiphyseal enlargement with associated gracile diaphysis: from hyperemia (appearances can be similar to juvenile rheumatoid arthritis and paralysis)
- secondary degenerative disease: symmetrical loss of joint cartilage involving all compartments equally with periarticular erosions and subchondral cysts, osteophytes and sclerosis.

◆ Knee

- widened intercondylar notch
- squared inferior margin of the patella
- bulbous femoral condyles
- flattened condylar surfaces

◆ Elbow

- enlarged radial head
- widened trochlear notch

◆ Ankle

- talar tilt: relative undergrowth of the lateral side of the tibial epiphysis leads to a pronated foot

ULTRASOUND

US is becoming increasingly useful as a tool for evaluating joint status in HA. It is inexpensive and accessible and the very young patient tolerates it well with no sedation requirements.

It is of particular use in the assessment of the acutely swollen joint. It may be clinically difficult to make the differentiation between an acute hemarthrosis or acute or chronic synovitis, but this differentiation can help to determine whether a patient requires factor replacement therapy or not. Most joint effusions appear dark (anechoic or hypoechoic) on sonography. A hemarthrosis may demonstrate altered echogenicity depending on the stage of degradation of the blood products. The normal synovial membrane is barely perceptible on US imaging. When inflamed however, there is diffuse or nodular synovial thickening. In addition, power Doppler sonography has the capability of demonstrating synovial vascularity in hemophilic joints.

MAGNETIC RESONANCE IMAGING (MRI)

MRI is the most complete imaging technique and the most sensitive for the diagnosis of musculoskeletal complications of hemophilia. It has been shown to be more sensitive in detecting the first signs of HA than both clinical examination and plain radiography. High correlation between the presence of osseous lesions on plain radiographs and the presence of synovial or cartilaginous changes on MRI, especially in the advanced stages of the disease, has been demonstrated. In the largest study comparing plain radiographs with MRI findings, chronic synovitis was demonstrated in 50% of patients in whom the plain radiograph was reported as normal. In those that did demonstrate plain film abnormalities, MRI revealed more profound disease in 70%. The sensitivity of MRI to detect the changes of early HA is high, but is lower for the elbow than for the knee or ankle.

Hemophilic arthropathy can develop anytime from the second decade of life, and sometimes earlier, depending on the severity of bleeding and its treatment. Conventional radiography is useful to monitor the advanced stages once cartilage or bone damage or both have occurred in the joint. It is inadequate for planning modern prevention or for evaluating early treatment efficacy. US is becoming an increasingly useful tool for evaluating joint and soft tissue status in HA. MRI is the most complete imaging technique and the most sensitive for the diagnosis of musculoskeletal complications of hemophilia.

■ REFERENCES:

1. Dr. Craig Hacking and Dr. Andrew Dixon et al. Hemophilic

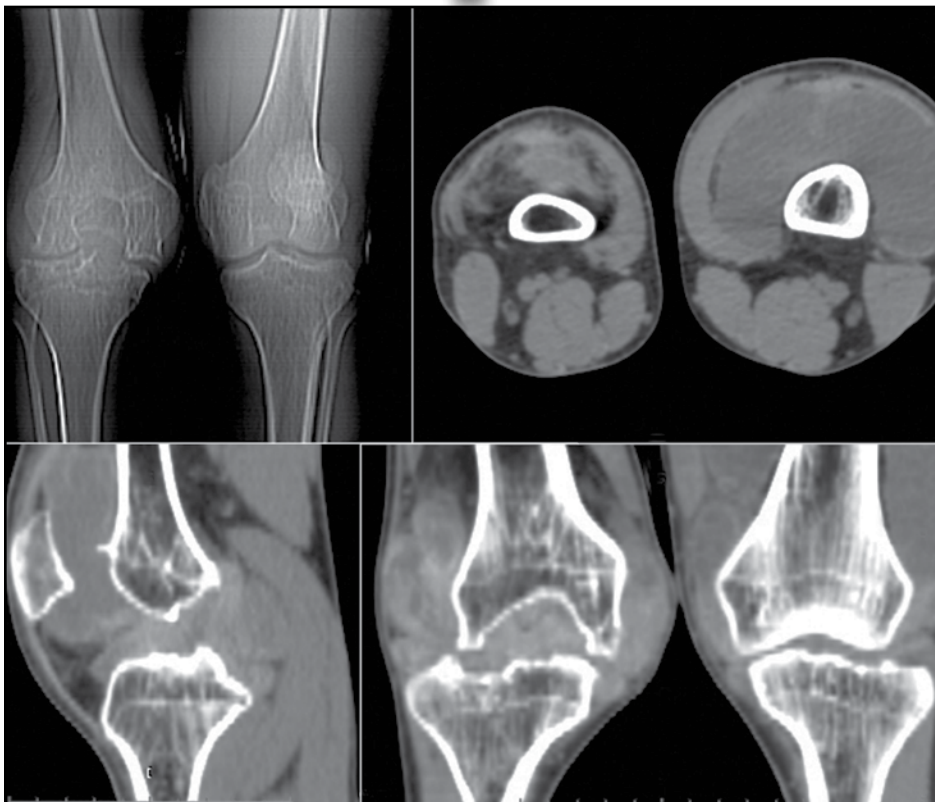
arthropathy. Radiopaedia Available at: <https://radiopaedia.org/cases/haemophilic-arthropathy-knee-1?lang=us> <https://radiopaedia.org/cases/haemophilic-arthropathy-elbow-1?lang=us> <https://radiopaedia.org/cases/haemophilic-arthropathy-ankle-mri-2?lang=us> <https://radiopaedia.org/cases/haemophilic-arthropathy-of-the-ankle?lang=us>

2. Cross S, Vaidya S, Fotiadis N. Hemophilic Arthropathy: A Review of Imaging and Staging. *Seminars in Ultrasound, CT and MRI* 2013; 34: 516–24. Available at: <https://www.sciencedirect.com/science/article/abs/pii/S0887217113000577>

com/science/article/abs/pii/S0887217113000577

3. Kilcoyne Rf, Nuss R. Radiological assessment of hemophilic arthropathy with emphasis on MRI findings *Haemophilia* 2003; 9:57–64 Available at: <https://onlinelibrary.wiley.com/doi/pdf/10.1046/j.1365-2516.9.s1.11.x>

Answer to Radiographic Quiz



Which of the following findings are present?

- T* Joint space irregularity and narrowing
- T* Subchondral sclerosis
- T* Subchondral cysts formation
- T* Periarticular osteopenia
- T* Epiphyseal overgrowth
- T* Joint effusion
- T* Widening notch of the distal femur
- T* Erosion of joint margins

Considering the patient's age, race and tomographic findings which is the most likely diagnosis.

- A. Degenerative osteoarthritis
- B. Hemophilic arthropathy**
- C. Primary synovial chondromatosis
- D. Pigmented villonodular synovitis