

Vulvar syringoma; Case Report and review

Mauricio Navarrete¹

Abstract

Syringomas are intraepidermal sweat gland tumors most often found in women. They are often seen on the lower eyelids; seldom may they be found in the vulva. Vulvar syringomas are commonly present as small, multiple, pigmented papules. They may cause discomfort and itching. The name syringoma is derived from the Greek word syrinx, [1]. This paper presents a case of a 29-year old female who presented complaining of mild vulvar itching and concerned about having an STD. Further interview revealed fear of carcinogenesis and a concomitant sexual dysfunction.

Key words

Vulvar syringomas, sweat gland tumors, papules, vulvar itching

INTRODUCTION

Epidemiology

In the US, syringomas in all its variants affect 1% of the population. There is no statistics for Belize. No racial predominance is evident, but females are more commonly affected than males. Though significantly more common under the eyelids other bodily locations are possible, with the vulvar type being the most uncommonly reported. They tend to begin appearing around the time of puberty. Vulvar syringoma is rarely reported in the literature. [1] [2]

Pathophysiology and clinical picture

Syringoma is generally considered a benign neoplasm that differentiates along eccrine lines. Syringomas are most likely histologically related to eccrine elements or pluripotential stem cells. [2]

Vulvar syringomas are usually distributed symmetrically on the labia majora of women in their third decade. They are usually asymptomatic but may be associated with occasional itching. They may especially be exacerbated during menstruation. The lesions are usually multiple and are small, skin color or yellow to light brown papules which may cause vulvar discomfort and frequent pruritus. [2]

Syringoma is usually located mostly in the superficial dermis and is composed of numerous small ducts embedded in a sclerotic stroma.

Histologic section of syringoma (figure 1) demonstrates numerous small ducts in a sclerotic stroma. The walls of the ducts are usually lined by 2 rows of cuboidal-to-flattened epithelial cells and have a lumen containing periodic-acid-Schiff-positive, eosinophilic, amorphous debris. Some of the ducts have elongated tails of epithelial cells, producing a

characteristic comma-shaped or tadpole appearance. Rarely, tumor cells may appear clear mainly due to glycogen accumulation. [2]

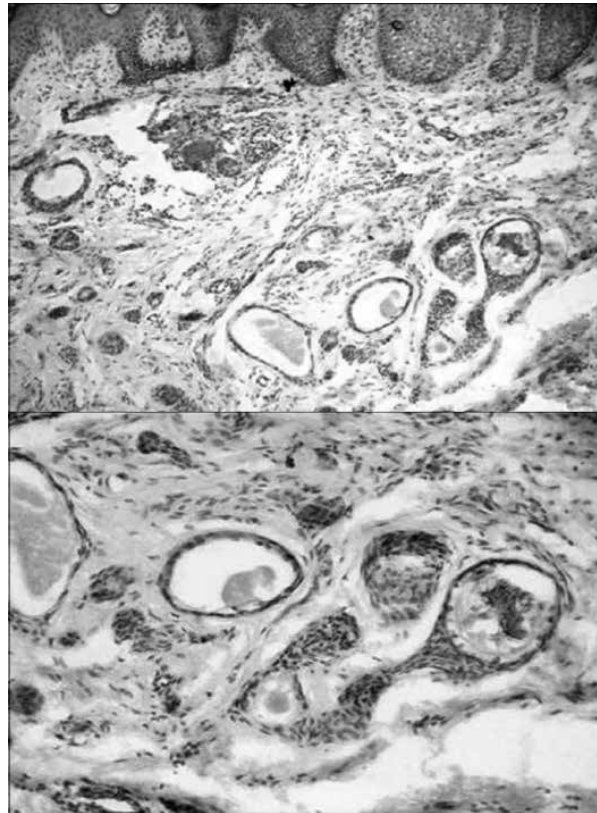


Figure 1. Histologic section of syringoma lesion.

.....
1 Corresponding author: Mauricio Navarrete, MD, BSc, Ob/Gyn Department of Obstetrics and Gynecology, Belize Healthcare Partners, Corner Chancellor & Blue Marlin Avenues, Belize City, Belize email: moznavataylor@hotmail.com

Differential Diagnosis[2]

It is important to exclude other common diseases of genitalia. Other disease entities include senile angiomas, Fox-Fordyce disease, condyloma acuminata, steatocystoma

multiplex, lymphangioma circumscriptum, lichen simplex chronicus and contact dermatitis, which can easily be differentiated on histopathology. Also, association of similar lesions in other parts of the body may aid in diagnosis. [3]

Treatment[2]

As they are harmless, treatment is not necessary in asymptomatic lesions. If the lesions are itchy, taking oral antihistamines might help. In case of severe itching, low to mild potency topical corticosteroids may be used. Potent corticosteroids are not recommended. Topical tretinoin and topical atropine have also been tried. [2] [3]

Otherwise, several treatment modalities have been tried with fair results, but there are no effective gold standard methods for complete cure. Treatment options may include excision, cryotherapy, carbon dioxide lasers and electro-desiccation. Several researches suggest carbon dioxide to be effective in treating the lesions. [1] [3] [4]

Prognosis

Prognosis is good. Treatment is, for the most part, cosmetic.

CLINICAL CASE

Patient: a 29 year old university student, P.M., single, G=0, with regular menstrual cycles, presents with no pertinent medical history. Previous appendectomy was the only surgical history. P.M. has no allergies or chronic use of medications; is a social drinker, non-smoker, non-drug user.

PM complains of vulvar “lumps”, which have been present for years at the time of consultation. She explains that she has attended many doctors and has been told that it could possibly represent a sexually transmitted disease or cancer. She had been provided with oral and topical treatments, but had seen no difference. She mentions that these “lumps” make her very self conscious and therefore she refrains from sexual activity due to fear of being asked about them or passing them on to someone.

Upon examination a cluster of hyperpigmented nodular lesions is observed running along both labia majora (Figure 2). No irritation or secretion is noted. No lymph nodes palpated regionally. Speculoscopy is normal. Nodules are painless. Occasional itching is reported. At this point, I decided to

perform a punch biopsy of one of the lesions.

Histopathological study reports features consistent with the diagnosis of syringoma.

After diagnosis, the patient decides to have all lesions removed. Due to the extent of the lesions on the external aspects of both labia majora, surgical excision is undertaken.

Patient is followed up for a period of 2 years; during this time, the vulvar area remains free of lesions

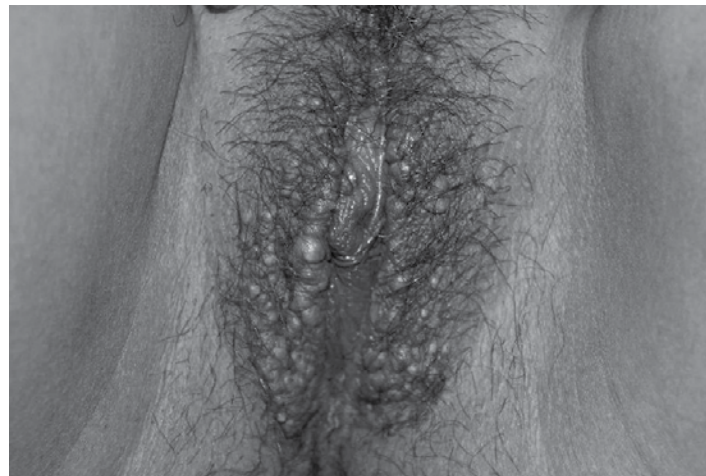

Figure 2. Syringoma hyperpigmented nodular lesions

REFERENCES

1. Mendiratta V, Harjai B, Gupta T. 2007;52:158-9.
2. Miranda JJ, Shahabi S, Salih S, Bahtiyar OM. Vulval syringoma: Report of a case and review of the literature. Yale J Bio Med 2002;75:207-10
3. Karam P, Benedetto AV. Syringomas: New approach to an old technique. Int J Dermatol 1996;35: 210-220
4. El-Domyati MM, Abdel-Raouf HM, El-Ammawi T, Abdel-Azim ES. Vulval Syringoma: First report of a case in an Egyptian female. Indian Dermatol Online J 2012;3:157-8

ACTIMIBE PLUS

Ezetimibe/Simvastatin

- Indicated for primary hypercholesterolemia
- Rapid cholesterol reduction due to the synergic action
- More effective than fibrates

