

Congenital duodenal obstruction by membrane in the newborn; case report

Yonet Piovét-Dorta¹ and José A. Gómez-Reyna²

Abstract

Congenital membrane type duodenal atresia is a rare pathology (1 x 10,000 to 40,000 live births), It is characterized by incomplete intestinal lumen obstruction with a small orifice or membrane. This happens due to failure of revacuolization at the stage of intestinal growth. Once birth occurs the main symptom is postprandial vomiting, and no weight gain of the newborn. If these cases are not diagnosed at this stage, there is exacerbation of vomiting that leads to important nutrient deficit. We report a child born at term (40 weeks), weighing 2700gr at birth, with diagnosis of congenital duodenal membrane type atresia after the first 72 hours. Exploratory laparotomy, resection of the intraluminal membrane and duododuodenostomy were performed by the Kimura technique, leaving transanastomotic feeding tube. Early enteral nutrition was achieved successfully. The child was discharged 14 days postsurgery.

Keywords

Intraluminal diaphragm, laparotomy, Kimura duodenoduodenostomy

■ INTRODUCTION

Duodenal obstruction occurs with a frequency of one per 2500 live births. It has been divided for its study into stenosis or incomplete obstruction, which may be due to a diaphragm or a membrane with or without perforation and atresia, or complete obstruction, which may be due to a fibrous muscular cord or complete absence of a duodenal segment leaving a gap (1). Diagnosis of fenestrated membranes is usually late, ranging from 5 weeks to 14 years, because this fenestration allows passage of liquid food. Surgical treatment is by laparotomy with duodenostomy and resection of the membrane or duodeno duodenal anastomosis. (2)

In recent years, laparoscopic correction is also reported, and reports of complete resection of the membranes by high frequency waves or laser and endoscopy. (3,4,5)

In our case, although diagnosis was not achieved in the first three days, we do not consider it late, since at this stage there are many diseases where vomiting is frequent and most do not require surgical treatment

■ CASE REPORT

1 Corresponding author, MD, Pediatrician, Karl Heusner Memorial Hospital (KMH), Belize City, Belize Email: ypiovet@yahoo.com

2 MD, Specialist in Internal Medicine, KMH, Belize City, Belize

The patient was a 7-day old female child, born by caesarean section, weighing 2700gr without prenatal pathological findings. Ultrasonography (USG) was normal. She was discharged on the day after delivery, but came back after 48 hours later because of vomiting (without description of its characteristics), and abdominal distension. She was admitted to the pediatric ward with a diagnosis of necrotizing enterocolitis (NEC) vs. sepsis.

LABORATORY TEST RESULTS ON ADMISSION

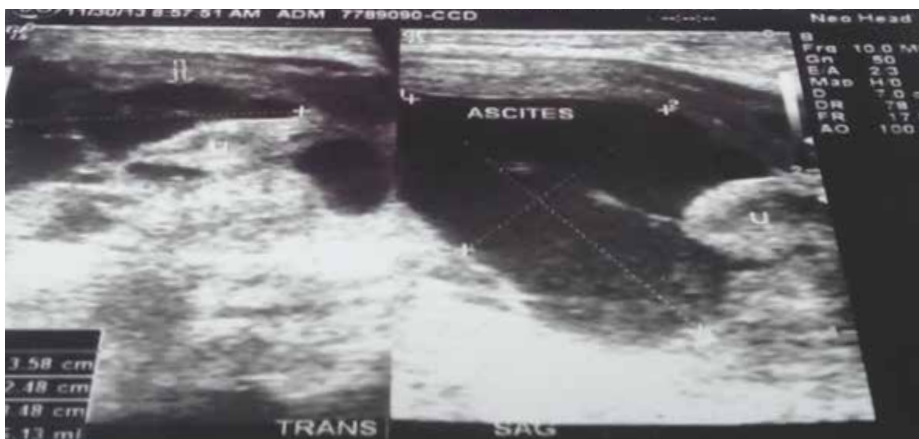
Hemoglobin 17.6 g/L
 Leucogram 10700.0 mm³
 Platelets 395.0 mm³
 Sodium 139.5 mmol/l
 Potassium 5.6 mmol/l
 Chlorine 106.0 mmol/l
 Creatinine 1.5 mg/dl
 Total protein 65 g/l
 Albumin 3.5 g/l
 Prothrombin time 28.2 seg
 Partial thromboplastin time 42.5 seg
 Blood group O +

Vomiting continued, becoming more frequent, and with bil-

ious characteristics; but the diagnosis of possible NEC vs. sepsis was maintained. The patient was given antimicrobials (ampicillin and gentamicin). The oral route was suspended; a nasogastric tube placed and intravenous fluids of dextrose with electrolytes administered. There were changes in the number of white blood cells, up to 15,000 and Hemoglobin decreased to 13.2 g/l. A change of antimicrobials (cefotaxime) was made and ultrasonography indicated. She was assessed by a surgeon.

ULTRASOUND

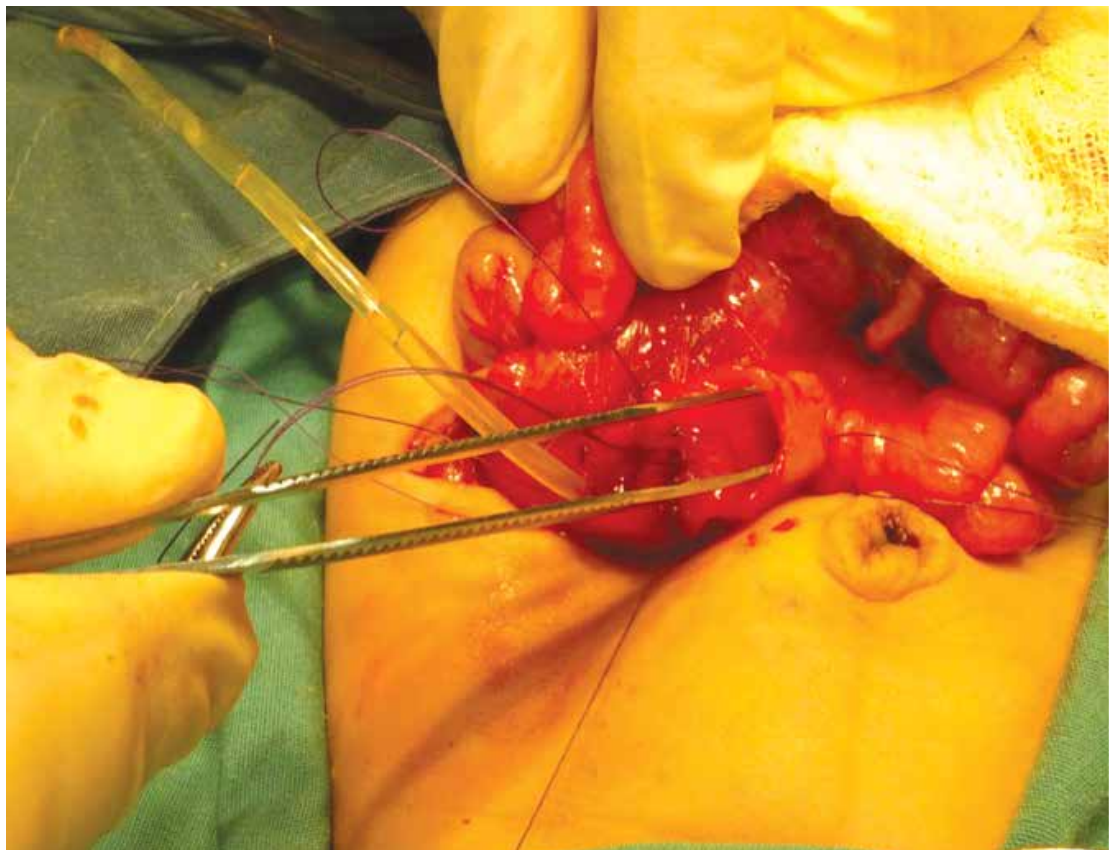
Ultrasonography findings were: dilatation of the stomach and first portion of the duodenum with increased gastric



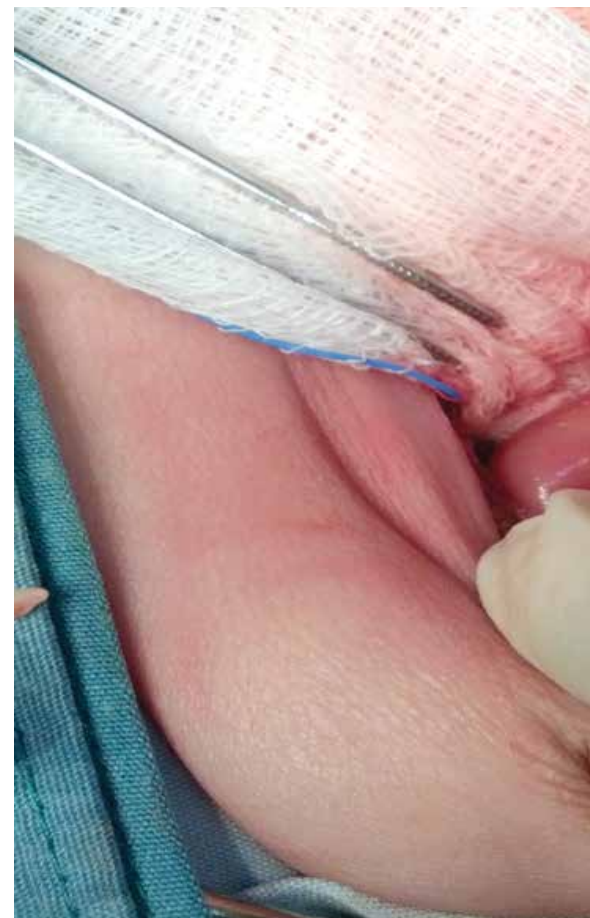
Ultrasonographic image

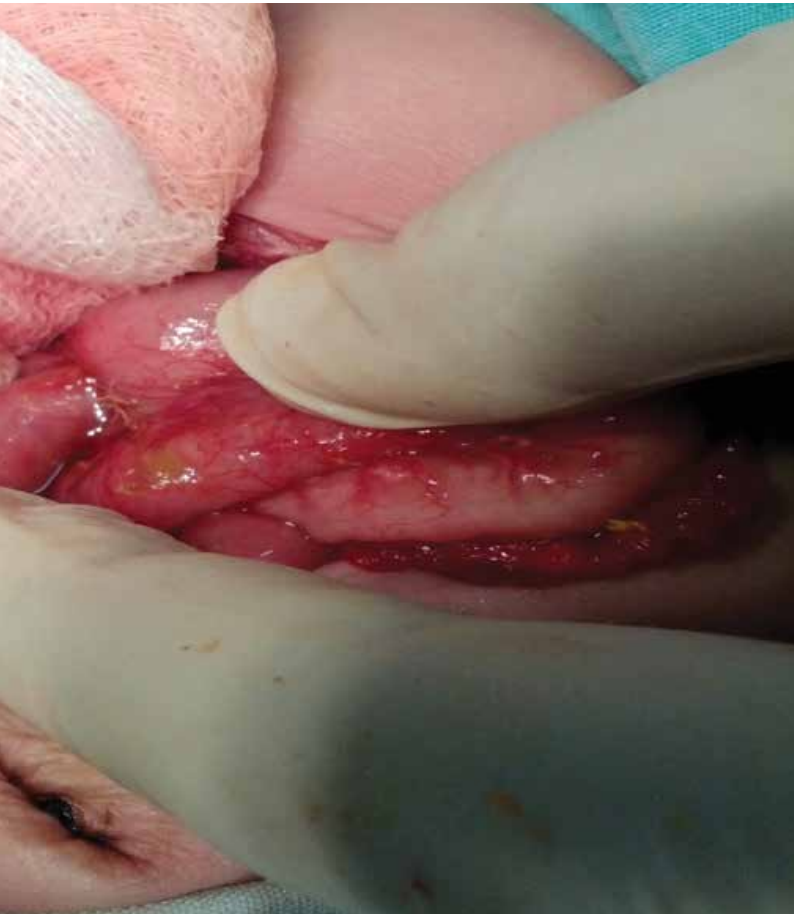peristalsis and free fluid, which is interpreted as ascites.

A contrast barium study was indicated. The findings were large gastric dilatation of the 1st and 2nd duodenal portions. There was delayed emptying and scarce passage of the contrast to the rest of the intestine and furthermore a small colon. She is taken to the operation room on the next day with a diagnosis of duodenal obstruction. Exploratory laparotomy was performed, finding that the patient had a diaphragm type duodenal obstruction. Duodenoduodenostomy was performed by the Kimura technique. A transanastomotic tube was left to facilitate early onset of feeding, always by breastfeeding, at three days postoperatively. Milk was well tolerated. She was dis-



Intraoperative image 1) Kimura type duodeno-duodenostomy





Intraoperative image 2) after performing anastomosis

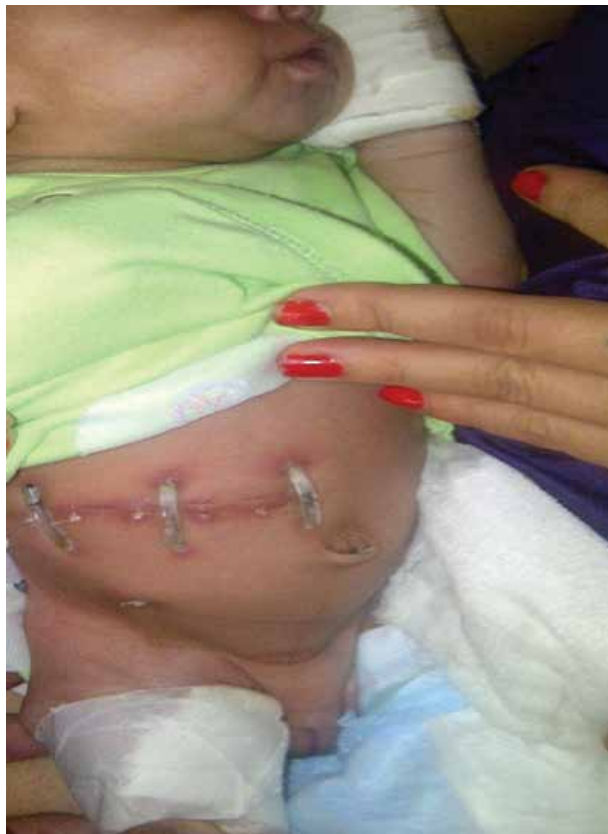

Image at discharge, 14 days after surgery

charged after 14 days having adequate weight gain and a favorable outcome, and ambulatory follow-up by surgery and pediatrics specialists was done.

■ DISCUSSION AND CONCLUSION

The etiology of duodenal membrane is still unclear, however the most accepted theory mentions lack of canalization during cephalocaudal epithelialization of an intestinal segment, mainly at the ampulla of Vater. The membrane is usually a few millimeters thick and has muscle fibers at its center, which are covered on both sides by intestinal epithelium. When fenestrated, the orifice can be central, eccentric or multiple with a diameter of 1 mm to 1 cm (average of 5 to 6 mm). This lesion usually occurs in more than 80% of the cases at the region of the ampulla (as in our patient). In the study by Mikaelsson and colleagues, it was associated to 75% with other anomalies, unlike our case, where other congenital malformations or alterations did not show in the prenatal ultrasound.

We may conclude by stating that, in our setting, newborn congenital malformations remain a problem. One, in which it is still difficult to achieve encouraging results for this complicated surgery. However, successes thereof have been increasing in our hospital.

■ REFERENCES

1. Mikaelsson C, Arnbjörnsson E, Kullendorff M. Membranous duodenal stenosis. *Acta Paediatr.* 1997; 86: 953–5.
2. Zia-ul-Miraj M, Madden NP, Brereton RJ. Simple incision: a safe and definitive procedure for congenital duodenal diaphragm. *J. Pediatric Surg.* 1999; 34: 1021–4.
3. Blanco Rodríguez G, Penchyna Grub J, Trujillo Ponce A, Nieto Zermeño J. Primer caso de corrección no quirúrgica de una atresia duodenal tipo membrana fenestrada en un recién nacido mediante sección y ampliación por endoscopia. *Bol Med Hosp Infant Mex* 2005; 62: 45-8.
4. Wyllie R. Intestinal atresia, stenosis, and malrotation. In: Kliegman RM, Behrman RE, Jenson HB, Stanton BF, eds. *Nelson Textbook of Pediatrics*. 18th ed. Philadelphia, Pa: Saunders Elsevier; 2011:chap 327.
5. Zhou W, Wang X, Li L, Mou Y, Cai X. Upper gastrointestinal tract obstruction due to congenital duodenal diaphragm. *Surg Radiol Anat* 2006, 28:325-7