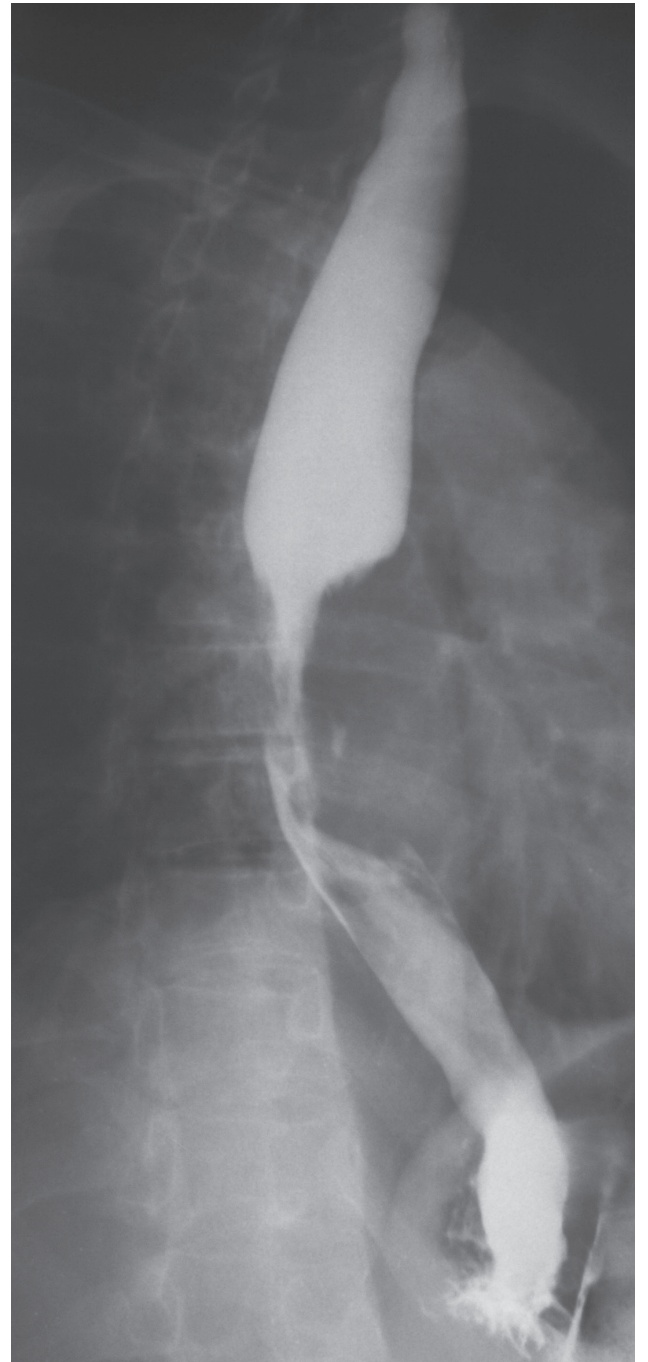
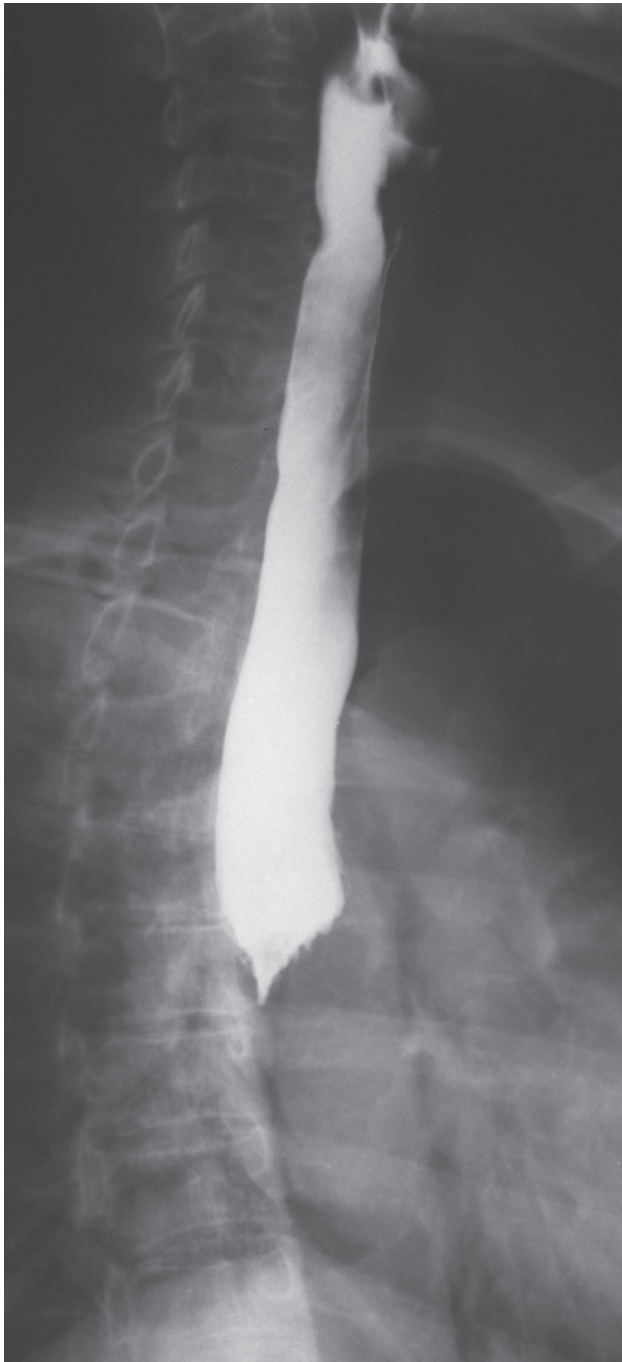
RADIOGRAPHIC QUIZ

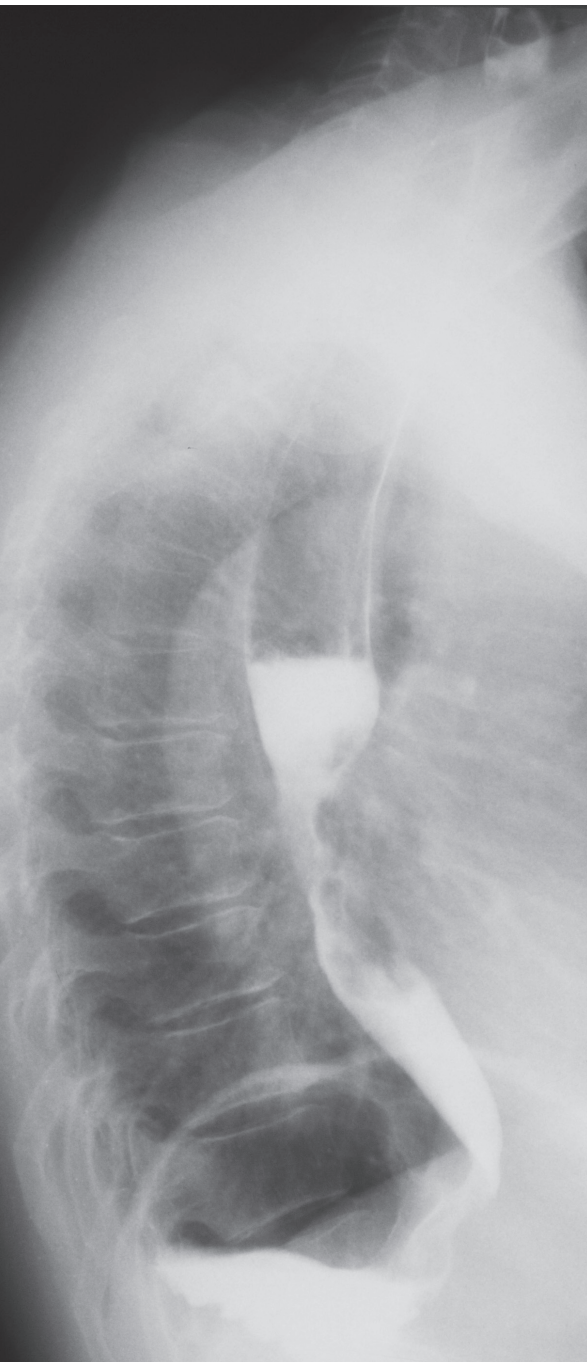
54 year-old woman with history of weight loss and difficulty swallowing solid foods.



• Please respond ...



Julio Manuel Díaz-Riverol¹



- Which choices characterize the findings?
Please respond with TRUE or FALSE

- Beak-like narrowing of the distal esophagus.*
- Retained foreign body with erosion of the esophagus.*
- Large Zenker's diverticulum.*
- Killian-Jamieson diverticulum.*
- Large amounts of fluid and debris, concern for imminent aspiration.*
- Irregular varicoid lesion narrowing the mid third of the esophagus.*

- What is the most likely diagnosis?

- Caustic ingestion.*
- Scleroderma esophagitis.*
- Barrett's esophagus.*
- Esophageal carcinoma.*
- Esophageal candidiasis.*
- Reflux esophagitis.*

- Which of the followings statements are correct?

- A. *Barium esophagography is a useful initial examination in the evaluation of a patient with esophageal complaints because it allows the assessment of esophageal morphology and motility.*
- B. *Esophageal endoscopy permits direct inspection and biopsy of the esophageal mucosa for histologic diagnosis.*
- C. *Esophagram is considered the best imaging modality for assessing achalasia.*
- D. *PET/CT can provide valuable information for esophageal malignancy staging.*
- A and C.*
- B and D.*
- All of the above are correct.*

- Respond True or False.

- CT scan has a notable limitation in diagnosis of metastatic lymph nodes because:*
- Lymph nodes may be enlarged due to infectious or inflammatory etiologies.*
- Subcentimeter lymph nodes may harbor metastatic tumor.*

Answer to Quiz in page 31