

A 56-year-old male patient referred to us with complaints of abdominal pain and weight loss. Panabdominal ultrasound and abdominal CT were performed. Ultrasound and tomographic images are presented.



• Please respond ...

Julio Manuel Díaz Riverol¹

Citation:
Díaz Riverol JM. Radiographic quiz
BJM 2021; 10(2):8-9

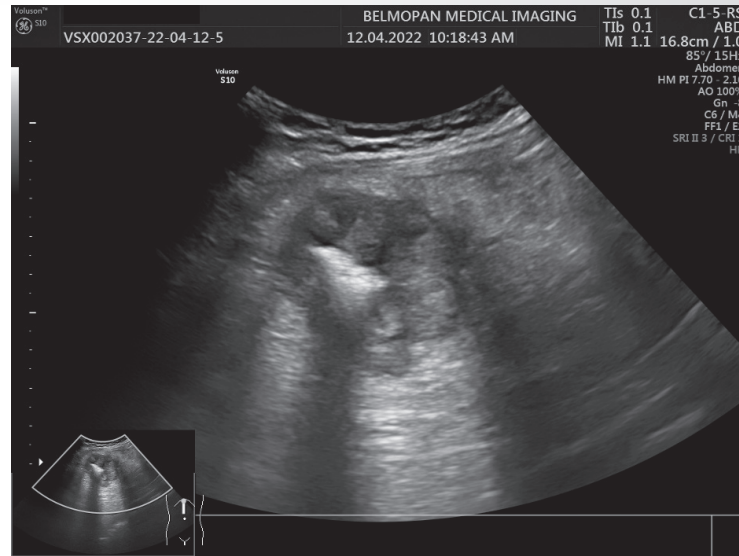


Image 1

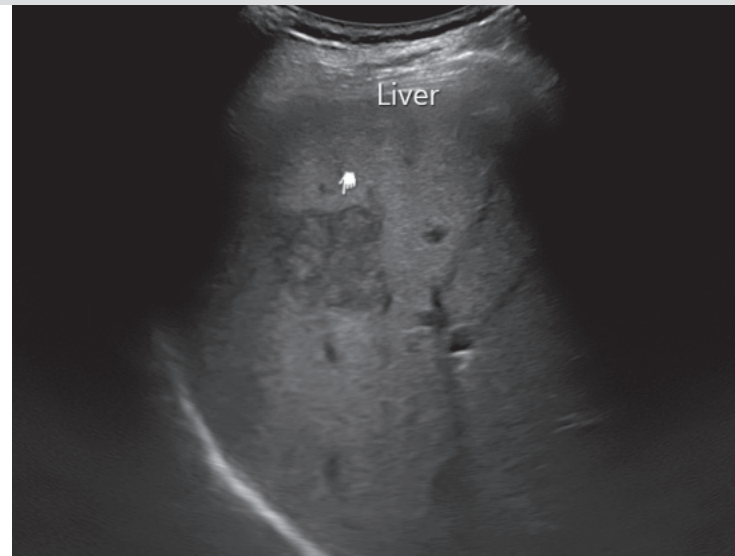

Image 2

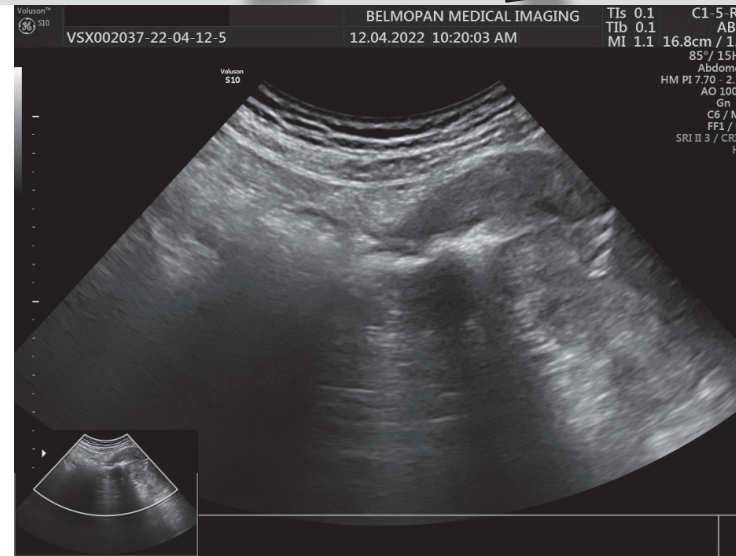


Image 3

Regarding to ultrasound images which organs are affected

- Liver and kidney
- Stomach and kidney
- Liver and colon
- Stomach and liver

The ultrasound findings are compatible with:

- Colon cancer and liver metastasis
- Renal mass and liver metastasis
- Stomach mass and liver cyst
- Stomach mass and kidney malformation

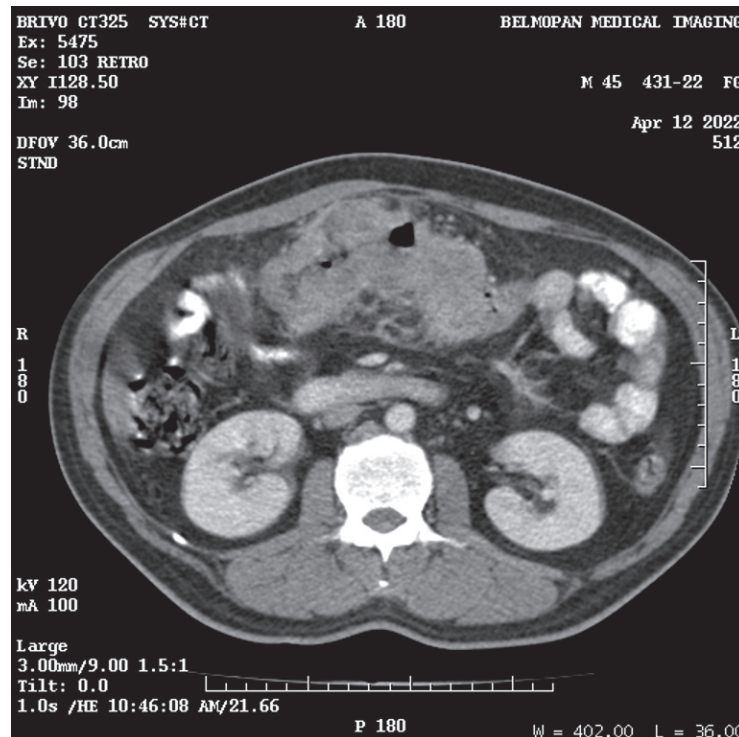


Image 4

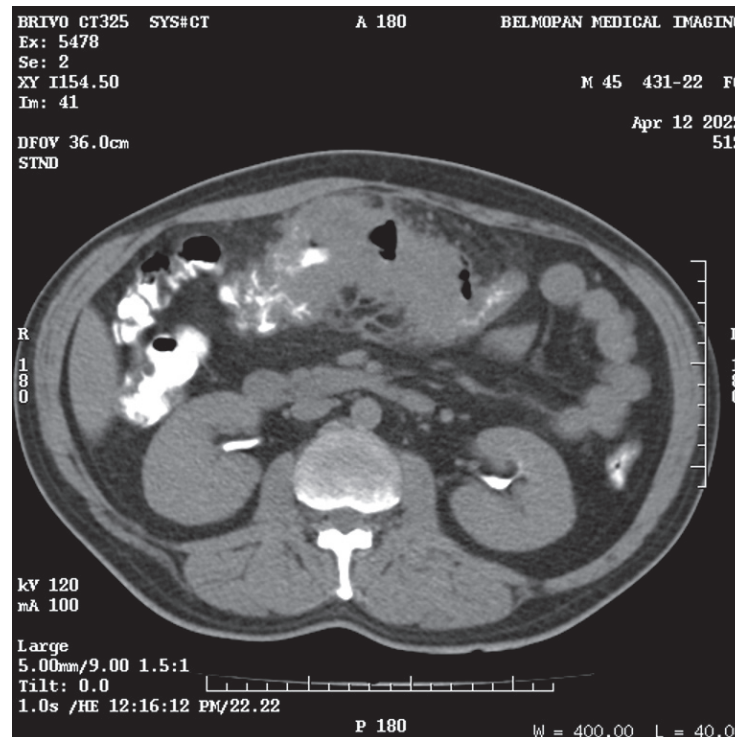


Image 5

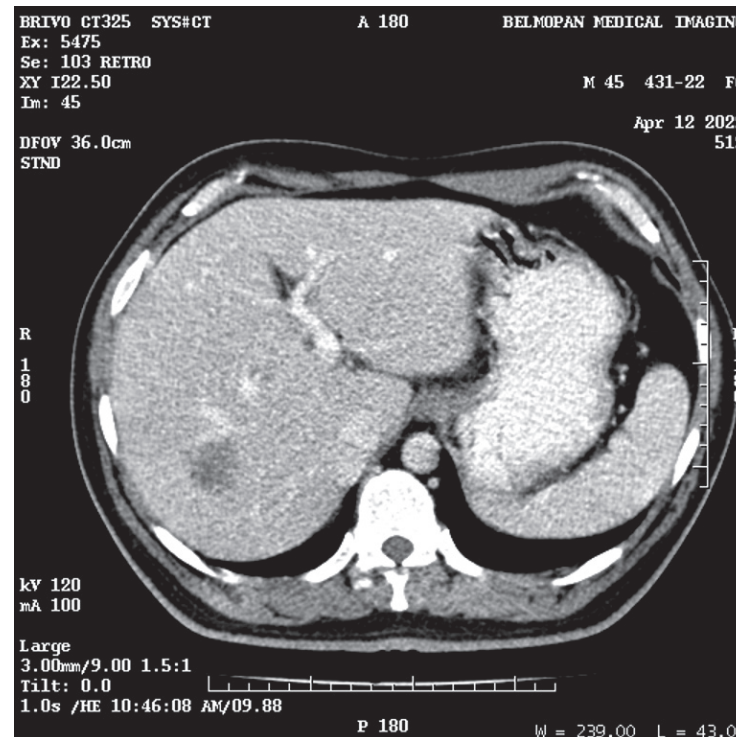


Image 6

Regarding to tomographic images which is the best description for the findings showed

- Soft tissue density that narrow the bowel lumen
- Hyperdense mass with focal calcifications
- Multiseptated mass
- Soft tissue density that narrow the bowel lumen and hypodense hepatic mass

What is your diagnostic?

- Gastric carcinoma and hepatic cyst
- Hepatocellular carcinoma and abdominal abscess
- Colon cancer and hepatic metastasis
- Pancreatic mass and hepatic metastasis