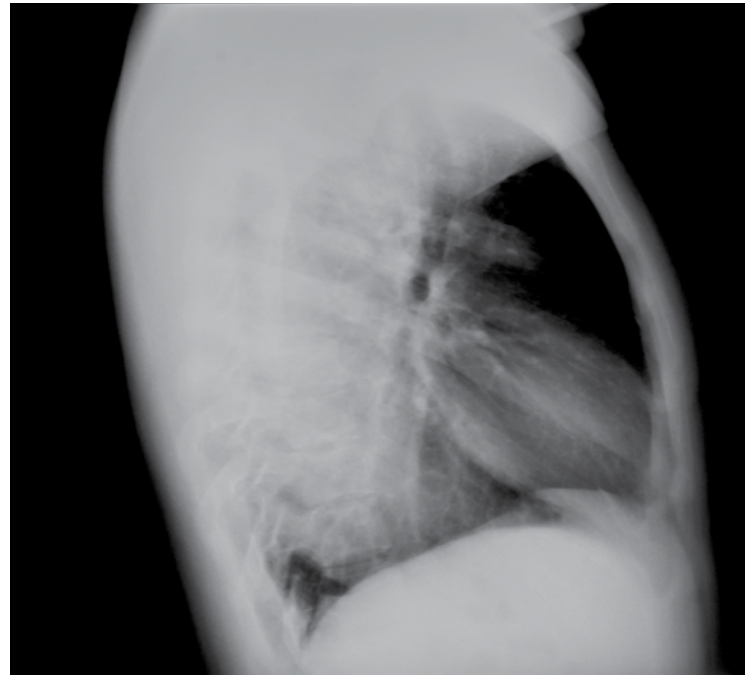
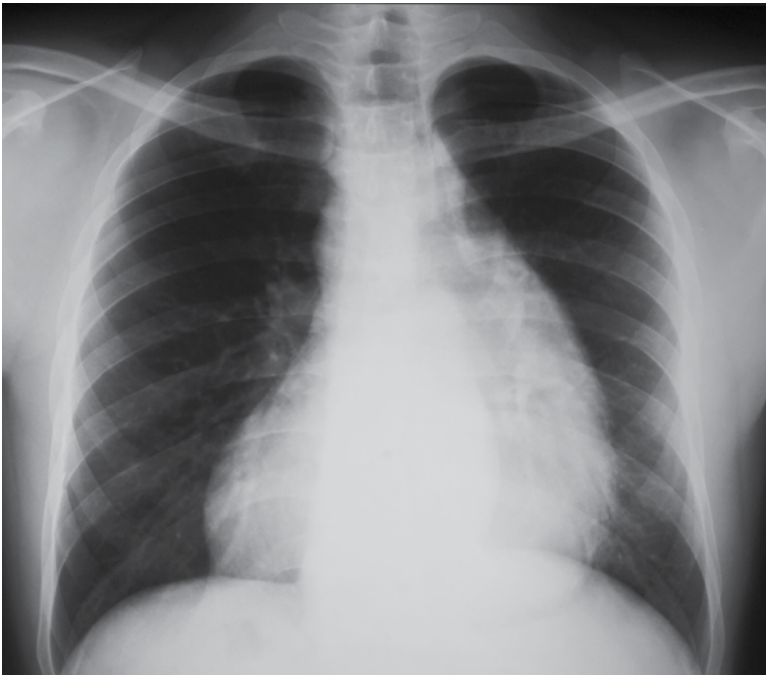
## Achalasia of the esophagus

### ■ REVIEW OF THE DISEASE

The word achalasia stems from the Greek term which means "does not relax".

Achalasia (primary achalasia) refers to a failure of organized esophageal peristalsis with impaired relaxation of the lower esophageal sphincter (LOS), resulting in often marked dilatation of the esophagus and food stasis. Obstruction of the distal esophagus (often due to tumor) has been termed "secondary achalasia" or "pseudoachalasia".

Primary achalasia is most frequently seen in middle and late adulthood (30-70 years of age) with no gender predilection. In most cases achalasia is idiopathic; however an identical appearance is seen in patients with Chagas disease. Authors differ as to whether they reserve the term achalasia for idiopathic cases, or whether they include Chagas disease.(1)

### ■ CLINICAL PRESENTATION

Achalasia has an insidious onset and disease progression is gradual. Patients typically experience symptoms for years prior to seeking medical attention. In one series of 87 consecutive patients with newly diagnosed achalasia, the mean duration of symptoms was 4.7 years prior to diagnosis. The delay in diagnosis was mainly due to misinterpretation of typical clinical features rather than atypical findings. Many patients are treated for other disorders such as gastroesophageal reflux disease before the diagnosis of achalasia is made.(2)

Typically patients present with dysphagia (for both solids and liquids, in comparison to dysphagia for solids only in cases of esophageal carcinoma), chest pain/discomfort and eventual regurgitation. Initially symptoms are intermittent. Patients may also present with complications of long

standing achalasia:

- esophageal carcinoma: is the most dreaded complication and it is seen in approximately 5%, and most often in the mid esophagus. It is thought to relate to the chronic irritation of the mucosa by stasis of food and secretions.
- aspiration pneumonia
- candida esophagitis
- acute airway obstruction: this is a rare complication requiring immediate esophageal decompression with nasogastric tube.

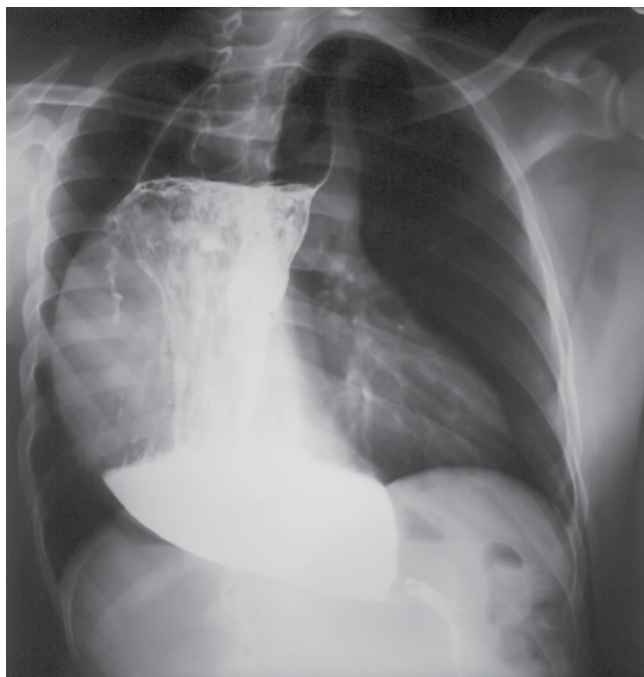
Peristalsis in the distal smooth muscle segment of the esophagus may be lost due to an abnormality of Auerbach plexus (responsible for smooth muscle relaxation), resulting in weak contractions that are uncoordinated and as a result non propulsive. The abnormality may also occur in the vagus nerve or in the dorsal motor nucleus of the vagus nerve.

The lower esophageal sphincter eventually fails to relax; either partially or completely, with elevated pressures demonstrated manometrically. Early in the course of achalasia, this lower esophageal sphincter tone may be normal or changes may be subtle.(3)

### ■ IMAGING FINDINGS

Diseases of the gastrointestinal tract may result in radiographic changes in the thorax. An abnormal chest radiograph is often the initial clue to the diagnosis of gastrointestinal disease. Primary esophageal disease, including achalasia, esophageal carcinoma, and esophageal perforation, often manifest diagnostic changes on chest radiographs.

The chest radiograph is usually normal in the early phase of achalasia. However, as the disease progresses, the dilated esophagus creates new interphases with the lung that can readily be observed on plain radiographs. The



azygoesophageal recess which is normally straight or slightly concave or convex to the right becomes more convex to the right as the esophagus dilates and is seen as an opacity behind the right border of the heart. The dilated esophagus also contacts the right lung above the azygos arch creating a soft tissue mass in the right superior mediastinum above the level of the azygos arch. Retained fluid and food debris allow for detection of air-fluid levels on chest radiographs obtained with the patient in upright position. Mass effect from the dilated esophagus can produce anterior displacement or bowing of the trachea. The gastric air bubble is often absent in cases of achalasia. Acute or chronic aspiration associated with poor esophageal emptying may also be seen and patchy bilateral alveolar opacities representing acute or chronic aspiration pneumonia may be seen.(4)

Esophagogram is an important study for diagnosis and further evaluation of suspected achalasia and is generally regarded as the best imaging modality for assessing achalasia. Motility, reflux, and aspiration can be evaluated in real-time with the determination of the presence or absence of primary peristalsis and incomplete relaxation of the lower esophageal sphincter. Severity of the disease can be assessed with advanced disease demonstrating a massively dilated esophagus. The distal esophagus may also have a tortuous, sigmoid appearance sometimes referred to as "sigmoid" esophagus. The typical image finding is a "bird-beak" appearance of the distal esophagus at the gastroesophageal junction. The esophagus proximal to this demonstrates smooth dilation. If this smooth dilation is disrupted by a ragged, ulcerated appearance or protruding lesion, malignancy should be suspected.

Double-contrast evaluation of the esophagus is particularly helpful in identifying potential malignancy with a sensitivity greater than 95%. Early lesions may appear plaque-like, as a sessile polyp or lobulation, or as an irregularity of the esophageal wall. More advanced cancers typically

demonstrate greater infiltration of the esophagus with polypoid, ulcerative, or varicoid appearance.

A barium swallow is not only able confirm that the esophagus is dilated, but also to assess mucosal abnormalities. Findings include:

- failure of normal peristalsis to clear the esophagus of barium when the patient is in recumbent position, with no primary waves identified
- uncoordinated, non-propulsive, tertiary contractions
- esophageal dilatation
- pooling or stasis of barium in the esophagus when the esophagus has become atonic or non-contractile (late feature in the disease)
- when the barium column is high enough (patient standing) the hydrostatic pressure can overcome the LOS pressure allowing passage of esophageal content
- incomplete LOS relaxation that is not coordinated with esophageal contraction
- bird beak sign

CT findings of achalasia demonstrate substantial esophageal dilation with an air-fluid level notably present in the supine patient. In the absence of malignancy, the dilated esophagus should appear smooth with marked abrupt narrowing at the distal esophagus in the region of the gastroesophageal junction. Wall thickness of the esophagus may be normal or decreased. Findings of chronic aspiration and aspiration pneumonia are also common given the persistently present fluid and debris within the esophagus. Long-standing achalasia is a risk factor for development of squamous cell carcinoma of the esophagus appearing as irregular wall thickening, a frank mass protruding into the lumen of the esophagus, or eccentric thickening at the gastroesophageal junction. Loss of fat planes between adjacent structures is seen with invading lesions, and there is the potential for fistulization due to infiltration of adjacent tissues as with this patient. Bowing of the trachea due to mass effect of an esophageal lesion can be seen. Lymphadenopathy may be present as a result of malignant involvement.

In addition, PET/CT can provide valuable information for esophageal cancer staging. Esophageal malignancy presents as a markedly FDG-avid lesion within the esophagus. Identification of FDG-avid lymphadenopathy allows for evaluation of the extent of metastatic nodal involvement for appropriate staging of disease. PET/CT can also help to identify occult metastatic lesions in distant locations such as the liver or help exclude metastatic disease in indeterminate lesions seen on other imaging.(5,6)

Patients with uncomplicated achalasia show a dilated thin walled esophagus filled with fluid/food debris.

#### ■ DIFFERENTIAL DIAGNOSIS

A number of entities may mimic achalasia, forming the so called 'achalasia pattern'.

- central and peripheral neuropathy
- scleroderma
- esophageal malignancy or gastric carcinoma: commonly referred as pseudoachalasia

- esophageal stricture
  - Chagas disease
  - anti-Hu antibodies from lung cancer
- Other esophageal disorders should also be considered:
- non-specific esophageal motility disorder
  - diffuse esophageal spasm
  - presbyoesophagus

**■ TREATMENT AND PROGNOSIS**

Treatment is aimed at allowing adequate drainage of the esophagus into the stomach. Options include

- calcium channel blockers
  - o ineffective in long term
  - o may be used while preparing for definitive treatment
- pneumatic dilatation
  - o effective in 85% of patients
  - o 3-5% risk of bleeding/perforation
- botulinum toxin injection
  - o lasts only 12 months per treatment
  - o may scar the submucosa leading to increased risk of perforation during subsequent myotomy
- surgical myotomy (Heller myotomy)
  - o 10-30% of patients develop gastro-esophageal reflux, and thus it is often combined with a Nissen fundoplication.(7,8)

**■ REFERENCES**

1. Bailey BJ, Johnson JT, Newlands SD. Bailey's Head and Neck

Surgery-Otolaryngology. Lippincott Williams & Wilkins. (2006)

2. Eckardt VF, Köhne U, Junginger T, Westermeier T. Risk factors for diagnostic delay in achalasia. Dig Dis Sci 1997; 42:580.

3. Howard PJ, Maher L, Pryde A, et al. Five year prospective study of the incidence, clinical features, and diagnosis of achalasia in Edinburgh. Gut 1992; 33:1011.

4. Timothy J. Cole, MD, Mary Ann Turner, MD. Manifestations of gastrointestinal disease on chest radiographs. Radiographics 1993; 13: 1013 – 1034.

5. Boeckxstaens GEE. Achalasia. Best Pract Res ClinGastroenterol. 2007;21(4):595-608.

6. Eckardt AJ, Eckardt VF. Current clinical approach to achalasia. World J Gastroenterol. 2009;15(32):3969-3975.

7. Grant LA BA (Hons) FRCR and Griffin N MB ChB MD FRCR. Grainger & Allison's Diagnostic Radiology Essentials. Churchill Livingstone, Elsevier Publ. 2010

8. Fauci AS, Braunwald E, Kasper DL, Hauser SL, Longo DL, Jameson JL. Harrison's Manual of Medicine. McGraw-Hill Professional. (2009)

- \_\_\_\_\_  T Right paramediastinal radiopacity
- \_\_\_\_\_  F Rib fractures
- \_\_\_\_\_  F Signs of pulmonary emphysema
- \_\_\_\_\_  T Anterior displacement and bowing of the trachea
- \_\_\_\_\_  T Considering the abnormality detected in the previous radiographs which study would you request next?
- \_\_\_\_\_  Plain chest CT
- \_\_\_\_\_  Contrast chest CT
- \_\_\_\_\_  X Barium swallow
- \_\_\_\_\_  Chest MRI
- \_\_\_\_\_  What is the most common clinical presentation in patients with this pathology?
- \_\_\_\_\_  Chest pain and discomfort
- \_\_\_\_\_  Dysphagia which is for both solids and fluids
- \_\_\_\_\_  Eventual regurgitation
- \_\_\_\_\_  X All of the above

- \_\_\_\_\_  T Widening of the mediastinum
- \_\_\_\_\_  F Decreased volume of the right lung
- \_\_\_\_\_  F Dilatation of the thoracic aorta
- \_\_\_\_\_  F Cardiomegaly
- \_\_\_\_\_  F with the quiz
- \_\_\_\_\_  Please respond true (T) or false (F). Review both views before proceeding
- \_\_\_\_\_  troesophageal junction consistent with achalasia.
- \_\_\_\_\_  The esophagogram reveals massive dilatation of the esophagus with the typical image of "bird-beak" appearance of the distal esophagus at the gas-troesophageal junction consistent with achalasia.
- \_\_\_\_\_  Note that the radiopacity continues below the line of the diaphragm. In the lateral view, anterior displacement and bowing of the trachea is visible.
- \_\_\_\_\_  The chest radiographs reveal right paramediastinal opacity which is behind the right border of the heart with convexity of the azygoesophageal recess.
- \_\_\_\_\_  The esophagogram reveals massive dilatation of the esophagus with the typical image of "bird-beak" appearance of the distal esophagus at the gas-troesophageal junction consistent with achalasia.
- \_\_\_\_\_  Please respond true (T) or false (F). Review both views before proceeding with the quiz

**Answer to Radiographic Quiz (Achalasia of the esophagus)**

