

A 42-years-old lady

referred to us with complaints of abdominal pain and fullness over the left side of the abdomen for two months duration. The pain was mild, dull aching, localized and continuous with a gradual increase in intensity over a period of time. Abdominal CT scan was requested.

Axial and reformatted CT scan images are presented.


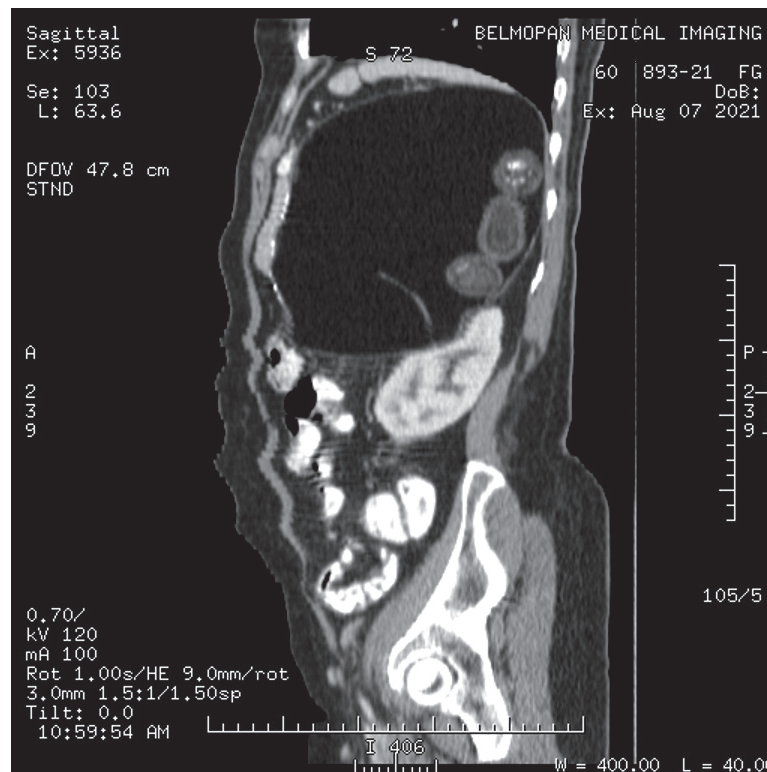
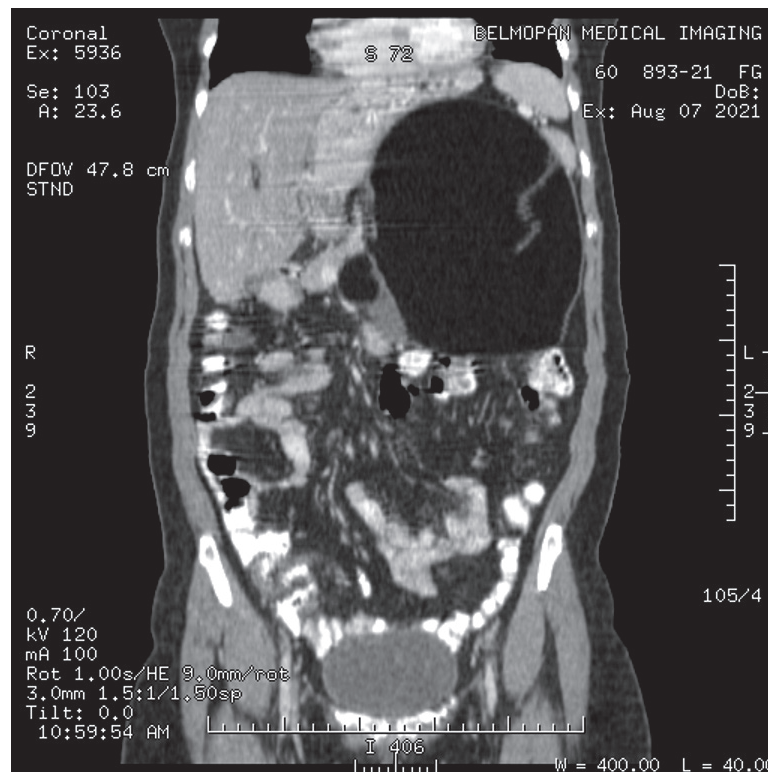
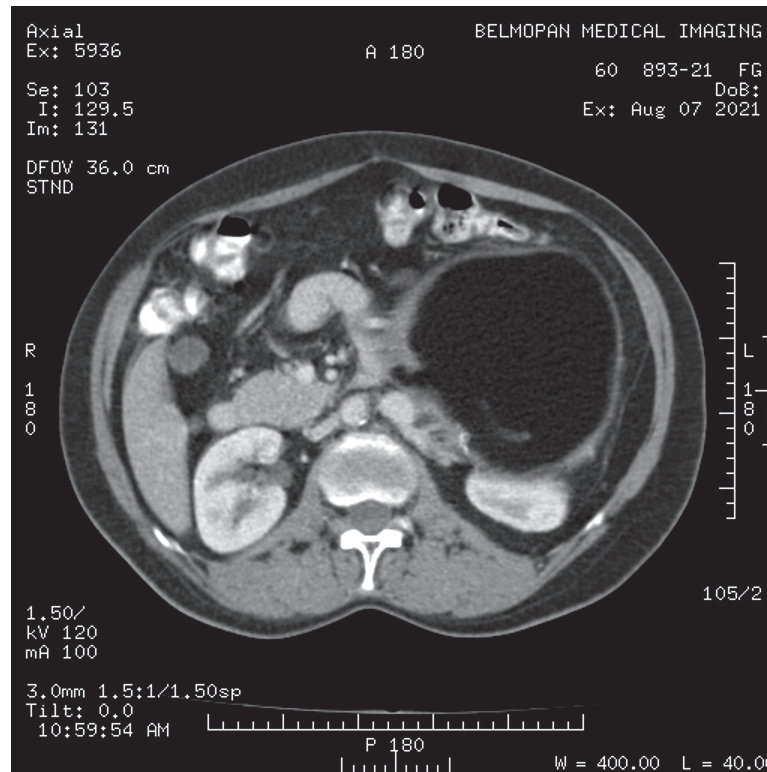
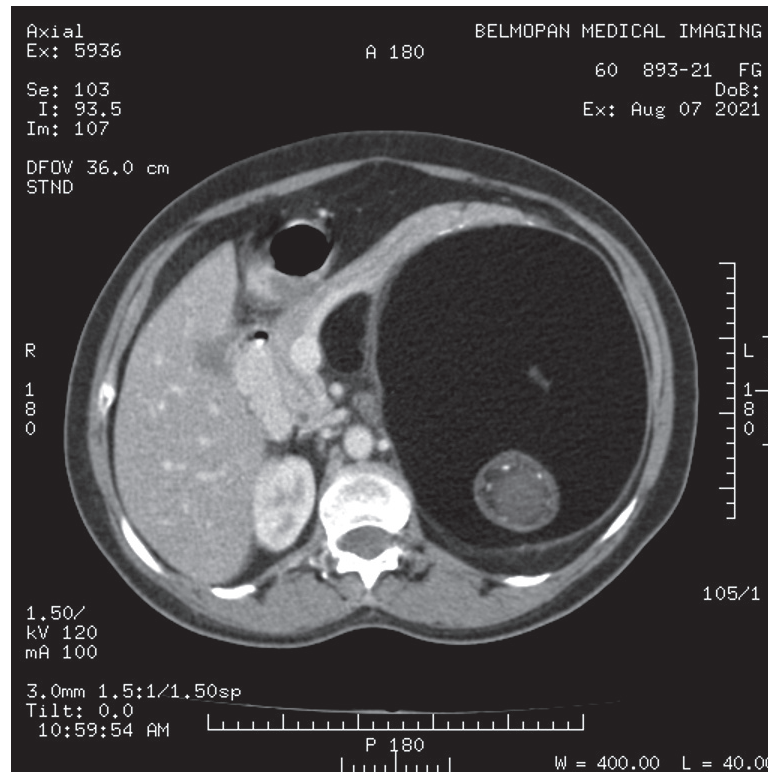


• Please respond ...

Julio Manuel Díaz Riverol¹

Citation:

Díaz Riverol JM. Radiographic quiz BJM 2021; 10(2):16-17



What is the main abnormality?

- Solid nodules with calcifications in the left hypochondrium
- Large left retroperitoneal predominantly fatty mass arising from the left kidney
- Large left renal cystic mass

There are inflammatory changes in the peritumoral fat.

- True
- False

There are vessels within the tumoral mass

- True
- False

The tomographic appearance suggests a giant exophytic left renal angiomyolipoma or a retroperitoneal liposarcoma.

- True
- False

The presurgical differentiation between giant exophytic renal angiomyolipoma and retroperitoneal sarcoma is considered an important point.

- True
- False

Sharp defect in renal parenchyma and enlarged vessels within the mass favor the diagnosis of renal angiomyolipoma.

- True
- False

Answers on page 42